



# Clinical and Radiographic Comparison of Instrumentation Time and Obturation Quality Using Pediatric Hand Files and Pediatric Rotary Files

Sakshi Chopra<sup>1</sup> Kamal Kishor Gupta<sup>1</sup> Ankita Gaur<sup>1</sup> Vasundhara Pathania<sup>1</sup> Ishant Sood<sup>1</sup> Sushen Radotra<sup>1</sup>

<sup>1</sup>Department of Pedodontics and Preventive Dentistry, Himachal Dental College, Himachal Pradesh, India

**Address for correspondence:** Sakshi Chopra, MDS, Department of Pedodontics and Preventive Dentistry, Himachal Dental College, Sunder Nagar, Himachal Pradesh 175019, India  
**E-mail:** sakshi.chopra0896@gmail.com

## Abstract

**Objective:** Rotary file systems, originally for endodontic procedures in permanent teeth, are now used in pediatric dentistry to save time and enhance compliance. New pediatric rotary files with heat-treated TiO<sub>2</sub> coatings and controlled memory are available for primary teeth, measuring 16 to 18 mm in length. This study compares the time and quality of obturation of primary molars using manual vs. pediatric rotary files.

**Materials and Methods:** The clinical study encompassed 60 primary molars in patients aged 4–8 years. Four different types of hand files (Hand K-Files, Kedo-SH) and rotary files (Kedo S Square, Pro AF Baby) were used for the pulpectomy procedures. Single visit pulpectomy was performed. Time taken for instrumentation was recorded from the beginning of instrumentation until the chemomechanical preparation of canals was finished using a stopwatch, and canals were obturated with Metapex. Obturation quality was evaluated radiographically, and the acquired data and instrumentation time were statistically analyzed.

**Results:** The Kedo-S-Square files (Group 4) had the shortest average duration of 15.2 minutes, while Pro AF Baby Gold files (Group 3) averaged 19.7 minutes, with hand files taking longer. Pro AF files achieved the highest quality of obturation, followed by Kedo S-Square and hand files.

**Conclusion:** Rotary instrumentation outperformed hand instrumentation regarding instrumentation time and obturation quality.

**Keywords:** Hand files, primary molars, rotary files,

## Introduction

In pediatric dentistry, the early loss of decaying primary teeth is a prevalent issue since it can negatively impact speech development, habits, facial growth, and the eruption sequence of permanent teeth.[1] Pulpectomy, which involves removing all pulpal tissue from primary teeth and replacing the root canals with a resorbable substance, is the recommended treatment for primary teeth with pulpitis and necrotic pulp.[2]

Endodontic treatment of primary teeth is difficult because of the intricate root canal structure. Children's anxiety can be decreased and treatment results can be enhanced by cutting down on treatment duration.[3,4] Hand-filling with stainless steel files is the traditional method for primary root canals, but it has drawbacks like longer preparation time, uneven shaping, canal transportation, and potential errors. In order to increase the accuracy of pulpectomy procedures on primary teeth, rotary instrumentation was introduced in pediatric den-

**How to cite this article:** Chopra S, Gupta KK, Gaur A, Pathania V, Sood I, Radotra S. Clinical and Radiographic Comparison of Instrumentation Time and Obturation Quality Using Pediatric Hand Files and Pediatric Rotary Files. J Pediatr Dent 2025;11(1):21-27



tistry.[5] Prior to 2016, rotary instrumentation in primary teeth was done with rotary files made for permanent teeth.[6] Originally designed for permanent teeth, NiTi tools such as ProTaper, M2, and K3 files have been modified for use with primary teeth. But in children's little mouths, their longer length and steady 6% and 8% taper can be problematic. To overcome these constraints, pediatric rotary files, which measure 16 or 17 mm, are now being created especially for primary teeth.[7]

The Pro AF Baby Gold file system from Dentobizz (Yavatmal, Maharashtra, India) includes five heat treatment memory files with consistent tapers of 4% and 6%, made of Ni-Ti controlled memory wire to improve canal centricity.[8] According to the Gomes et al[9] study, the use of technology in primary teeth endodontic treatment favored the gain of time and convenience of root canal preparation. Nevertheless, research is still required to solidify the method. Therefore, the purpose of this study is to evaluate and compare the instrumentation time and quality of obturation in primary molars using manual and rotary files.

## Materials and Methods

60 primary second molars of the mandibular arch patients, ages 4 to 8, who were seeking dental care, participated in the study. The tooth was not the factor that affected the filling quality or timing. The parents of the patients gave their informed agreement, and the study was authorized by the Institutional Ethical Committee Review Board.

### Inclusion criteria

- Children between the ages of four and eight.
- Patients who score between three and four on Frankl's behavior rating scale, meaning they are positive and unquestionably positive.
- The minimum of two-thirds of the residual root length.
- Enough tooth structure for a rubber dam clamp to be applied.
- Permanent pulpitis in the teeth of the primary molars.
- Primary molar teeth that have an abscess or necrotic canals.
- Radiolucent regions in the periradicular or furcal regions.

### Non-inclusion criteria

- During the surgery, patients exhibited disruptive behavior (a score of 1 or 2 on Frankl's behavior assessment scale indicates a decidedly poor outcome).

- Too much movement, pulpal floor perforation, and clinically unrestorable teeth.
- Molars that exhibit pathologic root resorption in excess of one-third.

### Study design

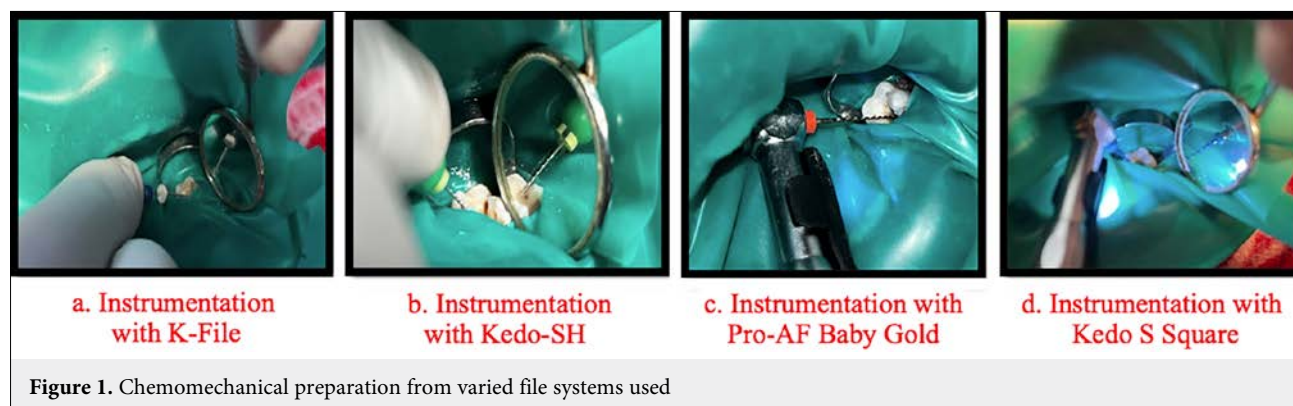
In four equal groups, sixty primary molars underwent pulpectomy using hand files and different pediatric rotary files.

- Group 1 (n=15): Manual instrumentation using K-Files (Mani, Takanezawa, Tochigi, Japan).
- Group 2 (n=15): Manual instrumentation using Kedo-SH (Reegan Dental Care Pvt. Ltd., Chennai, Tamil Nadu, India).
- Group 3 (n=15): Rotary instrumentation using Pro AF Baby Gold (Dentobizz, Yavatmal, Maharashtra, India).
- Group 4 (n=15): Rotary instrumentation using Kedo-S Square (Reegan Dental Care Pvt. Ltd., Chennai, Tamil Nadu, India).

### Treatment procedure

All of the teeth chosen for the study underwent a single-visit pulpectomy by the same operator. Local anesthetic was given using 2% lignocaine and 1:2,00,000 adrenaline. After obturation, the teeth were exposed to intraoral periapical radiography, and the pulpectomy process was performed under rubber dam isolation.

1. **Preparation of access cavity:** Using a handpiece (NSK PANA AIR MB2, Tochigi, Japan) and a 330-pear-shaped bur (Mani Inc., Takanezawa, Tochigi, Japan), the initial step was to remove carious tissue and create an access aperture. For additional deroofing, the Endo Z bur (Dentsply Sirona, York, Pennsylvania, USA) was employed. A spoon excavator was used to remove the coronal pulp, and a DG 16 endodontic explorer was used to investigate the canal orifices. H-Files and a barbed broach were used to extract the pulp, and 2.5% sodium hypochlorite and 0.9% normal saline were used to irrigate the pulp chamber.
2. **Determining the working length:** While irrigating the pulp chamber, the patency was established using a no. 15 or 20 K-file. Taking into account the mesial and distal cusps, the working length was maintained 1 mm below the radiographic apex using Ingle's approach.
3. **Chemomechanical Preparation:** Proper cleaning of primary teeth is crucial as different file systems can affect efficiency and effectiveness. Chemomechanical preparation may vary based on the file system used.



- **Group 1:** Hand instrumentation was completed by hand. K file (Mani, Takanezawa Tochigi, Japan) up to no 40 K (Kerr) file using quarter turn and pull motion (Fig. 1a).
  - **Group 2:** Canals were located with a 15-size white Kedo SH hand file. Pulp was extracted using a 20-size yellow Kedo SH hand file. Mesio Buccal and mesiolingual canals were shaped with a D1 Kedo SH hand file, and the distal canal was prepared with an E1 Kedo SH hand files. Necessary irrigation procedures were performed (Fig. 1b).
  - **Group 3:** Files lubricated with 17% EDTA were used to prepare root canals. A #15 K-File (Mani, Japan) was used to check the initial patency. The Pro AF Baby Gold NiTi pediatric rotary file was then used at 300 RPM, 2N torque, and auto-reverse mode. After using the B1(#20/0.04) file until the working length was achieved, a # 10 K file was used for recapitulation which was followed by irrigation. The B2 (#25/0.04) file from was then used, and the B2 and B3 (#30/04) files were used for broader canals. Using pecking and lateral brushing motions, extensive irrigation and recapitulation were carried out with #10 K-file until the working length was reached (Fig. 1c).
  - **Group 4:** Using files lubricated with 17% EDTA, the canals were prepared. For initial patency, a #15 No. K-File was utilized. Then, using a #20 K file and Kedo S 'Square' rotary files (P1) driven by an endodontic motor set to 300 rpm and 2.2 N/cm torque, the canals were prepared. During instrumentation, intermittent irrigation was employed (Fig. 1d).
4. **Obturation:** Glass ionomer cement (Ketac Molar, 3M ESPE, St. Paul, MN, USA) was used to seal the canals after they had been filled with Metapex (Meta Biomed Co. Ltd., Korea) in a single visit. After one week of pulpectomy procedure, stainless-steel crowns (3M

ESPE, St. Paul, MN, USA) were cemented with GIC luting cement type I (Ketac Cem, 3M ESPE, St. Paul, MN, USA) after a postoperative radiograph was taken to assess the quality of the filling.

Compared to CBCT and analogue radiography, Matherne et al[10] found that digital radiography has several benefits, such as lower patient exposure, instant image access, and better tiny void detection.[10] Due to its minimal invasiveness, widespread clinical application, and cost-effectiveness, we chose digital radiography to assess obturation quality in our current study.

### Assessment of teeth

#### *Instrumentation time and obturation quality*

From the beginning of the process until the canals were ready, the duration of the instrumentation was noted. After the last saline irrigation, the timer stopped. It started with the first file. The quality of obturation was assessed using the standards provided by Coll and Sadrin (1996).[11]

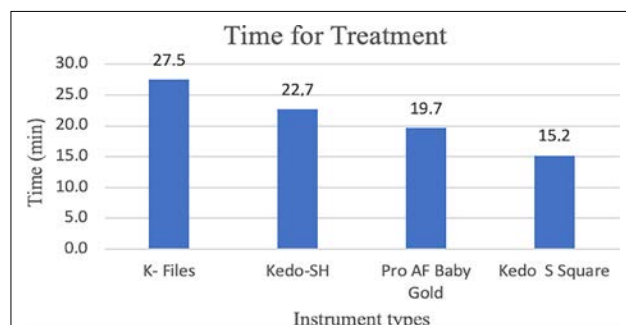
- Score 1 (under-filling): Every canal had filling that was more than 2 mm below the apex.
- Score 2 (ideal filling): Up to 2 mm short of the radiographic apex or at the end of one or more canals with obturating material.
- Score 3 (overfilling): Any canals with obturating material that extends over the radiographic apex.
- Presence or absence of voids.

The obtained data was statistically examined using the ANOVA, post-hoc, and Chi-Square tests, and the results were compared. 0.05 was the significance level.

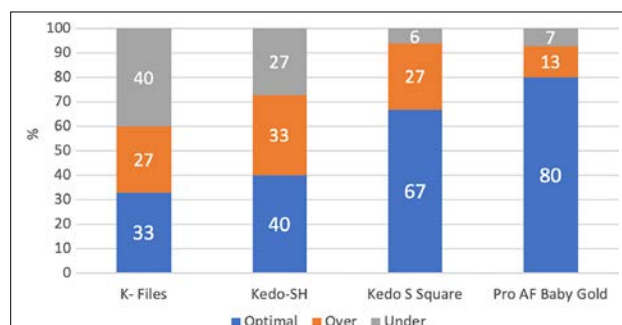
## Results

### **Analysis of time required in different instruments**

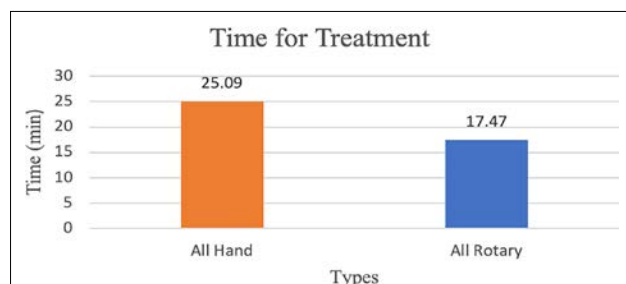
Bar diagram of treatment time (in minutes) needed with different instruments can be seen in Figure 2.



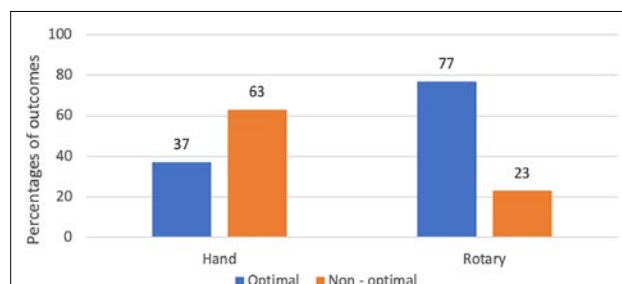
**Figure 2.** Bar diagram of treatment time (in minutes) needed with different instruments



**Figure 4.** Stacked bar diagram of percentages of quality (optimal, over, and under) obtained with different instruments



**Figure 3.** Bar diagram of treatment time (in minutes) required with hand and rotary files



**Figure 5.** Bar diagram showing obturation quality obtained with hand and rotary files

Bar diagram of treatment time (in minutes) required with hand and rotary files can be seen in Figure 3.

A chi-square test was conducted to analyze the difference between the groups in Figure 3. The analysis revealed a statistically significant result (0.0001). A one-way ANOVA showed a highly significant effect of the treatment method on instrumentation time ( $F(3, 56)=73.36$ ,  $p<0.0001$ ). Post hoc tests showed significant differences in time scores between treatment groups, indicating non-homogeneity. The mean duration of treatment of all patients undergoing rotary Files ( $N=30$ ), when compared with the mean duration of manual Files ( $N=30$ ), showed a highly significant difference ( $p<0.0001$ ).

### Analysis of quality outcomes

Stacked bar diagram of percentages of quality (optimal, over, and under) obtained with different instruments can be seen in Figure 4.

Bar diagram showing obturation quality obtained with hand and rotary files can be seen in Figure 5.

A chi-square test was conducted to compare the three categories of quality outcomes (optimal, under, and over) across different instrument types. The analysis revealed a statistically non-significant association  $\chi^2(6,$

$60)=11.24$ ,  $p=0.801$ . The paired comparison between the different instrument procedures showed that the outcome frequencies with K file and outcome with Kedo SH are not statistically significant,  $\chi^2(1, 30)=0.60$ ,  $p=0.74$ , indicating two hand instrument procedures yielded similar results about quality outcomes.

Similarly, when the two rotary instruments were compared, the frequencies did not show any significant difference,  $\chi^2(1, 30)=0.85$ ,  $p=0.65$ , indicating a similar outcome from rotary methods regarding quality.

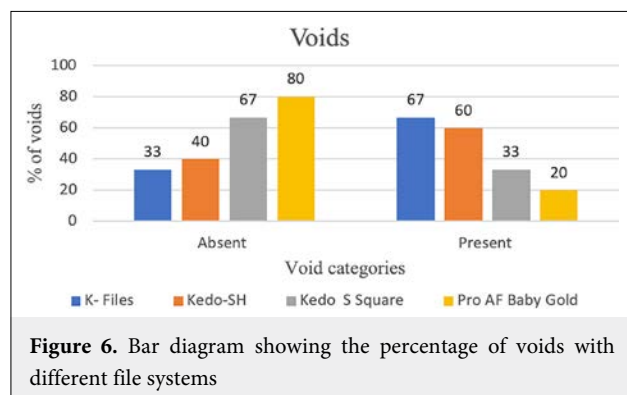
The other method of rotary file system, Pro AF baby, when compared with the K file, yielded a statistically significant result, any significant difference,  $\chi^2(1, 30)=7.12$ ,  $p=0.03$ , but no statistically significant association when compared with Kedo SH,  $\chi^2(1, 30)=5.08$ ,  $p=0.08$ .

The optimal and non-optimal outcomes in all manual ( $N=30$ ) and all rotary ( $N=30$ ) treatment modes about these variables appeared to be significant,  $\chi^2(1, N=60)=8.148$ ,  $p=0.0043$ , indicating rotary file system modes, are more likely to give optimal outcomes as compared to hand treatment modes.

### Analysis of voids

Bar diagram showing the percentage of voids with different file systems can be seen in Figure 6.





Bar diagram showing the percentage of voids with hand and rotary files can be seen in Figure 7.

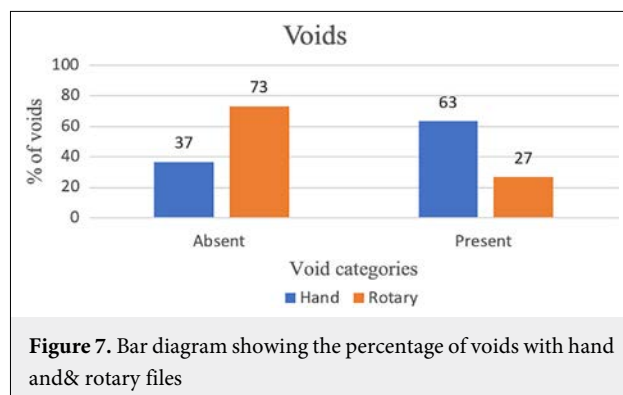
A chi-square test was conducted to compare the presence and absence of voids across treatments using different types of files. The analysis revealed a statistically significant chi-square value of  $\chi^2(2)=8.82$ , indicating a significant association between different file systems and quality outcomes,  $p=0.32$ .

The presence and absence of voids in all manual ( $N=30$ ) and all rotary files ( $N=30$ ) were appeared to be significant,  $\chi^2(1, N=60)=8.148$ ,  $p=0.004$ , indicating rotary file system modes are more likely produce fewer voids as compared to hand treatment modes.

## Discussion

Endodontic procedures on primary teeth are frequently complicated by a number of factors, such as the length of the primary dentition, the integrity of the coronal structure, the morphology of the root canal, and spontaneous resorption.[12] According to Brar et al[13], pulpectomy success rates were greater for primary teeth with little to no preoperative root resorption than for those with significant resorption.[13] Children ages 4 to 8 with fully developed, nonresorbed, or mildly resorbed roots were the subject of the current study. The pulpectomy in this study was performed in a single visit because it eliminates the possibility of contamination and/or bacterial regrowth in the root canal, which could occur over multiple treatment sessions.[14] Furthermore, a child with anxiety is expected to experience less stress and decreases procedure time.

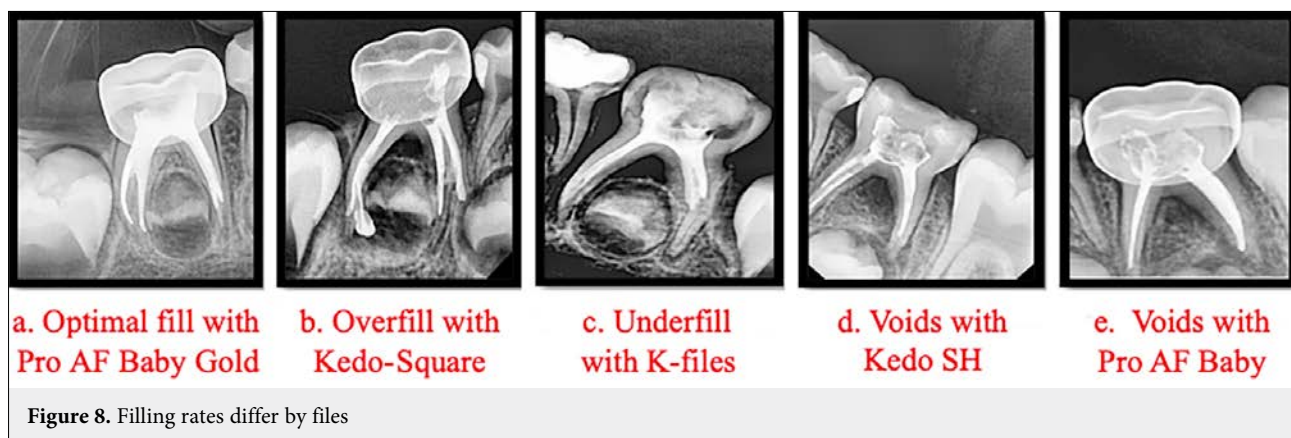Zinc oxide eugenol has a slow resorption rate and can harm the development of permanent tooth bud.[15] Metapex and Vitapex, which contain calcium hydroxide and iodoform, are commonly used for filling root canals in primary teeth. Metapex is cost-effective and highly



successful, with a 96% to 100% success rate.[15] The capillary tip delivery method for Metapex is the most effective technique for filling.[15] Hence, we opted for Metapex in our study. Manual stainless-steel files introduced in 1960 caused root canal transportation due to a lack of flexibility.[7] NiTi instruments were developed to address this issue, with unique properties (super elasticity, shape memory, and strength) reducing errors.[7] Using NiTi ProFile 0.04 taper rotary files, it's been performed pulpectomy procedures and found that this method reliably and consistently filled the root canal.[8] As the root canals of primary molars are ribbon-shaped, Kuo et al[16] proposed NiTi rotary files for primary teeth. In 2017, the Kedo file system was introduced by Ganesh Jeevanandan.[17] Kedo-S by Reegan Dental Care Pvt. Ltd. is the first pediatric rotary file system. The Kedo-S Square files from the fourth generation, is a single file system, were the pediatric rotary files used in this study. The overall length of these files (A1 for anterior teeth, P1 for molars) is 16 mm, with a working length of 12 mm.[18] They are easier to use without creating lateral perforations because of their special V-V taper design, which resembles the root canal shape of primary teeth.[18] Because of their  $\text{TiO}_2$  coating, these files also offer benefits like greater flexibility, less dentin removal, and enhanced resistance to cyclic fatigue.

Pro AF Baby Gold file from Dentobizz, India, is a five-file system that uses NiTi CM wire technology with a constant taper of 4% or 6%. The B1(#20–04%), B2(#25–04%), B3(#25–06%), B4(#30–04%), and B5(#40–04%) files are used for different canal types, with B1 and B2 for narrow canals and B3 and B4 for wide canals(distal/palatal). These files have a short length of 17mm for increased safety and comfort during procedures.[19]

According to studies by Makarem et al[20], rotary files increase operator efficiency by lowering the demand for manual dexterity, which leads to faster procedures. This conclusion is supported in the current study.



The study found significant differences in average instrumentation time among the four groups. Kedo S Square had the quickest instrumentation time followed by Pro AF Baby, Kedo SH, and K-files. Implementing rotary instruments helps in minimizing fatigue and increasing operator's efficacy by reducing instrumentation time. The current results were comparable to results obtained by Ochoa-Romero et al[3] in 2011, Makerem et al[20] in 2014, Jeevanandan & Govindaraju[21], Panchal et al[22], Govindaraju et al[23], and Shah et al[24].

In a 2017 survey, 66% of dentists stressed on significance of a specialized rotary file for pediatric patients, citing better accessibility and faster preparation as crucial factors.[25]

Managing primary teeth infection involves root canal debridement and filling with a resorbable substance. [15] Research indicates that teeth filled entirely up to or slightly below the apex have a higher success rate than overfilled or underfilled teeth.[11]

The results of this study showed that because of their gradual taper, conical preparation, and wider cervical enlargement, rotary files (Pro AF Baby and Kedo S Square) were superior to manual files (Kedo-SH and hand K-Files) in producing the best canal filling (Fig. 5). The rotary files consistently achieved a more uniform filling of the obturating material. Present obtained results are same as by findings Govinda et al[7].

Pro AF Baby Gold rotary files had the highest optimal filling rate in the current study (Fig. 8a). These were followed by Kedo S Square pediatric rotary files (Fig. 8b), Kedo SH files (Fig. 8d) and manual K-files (Fig. 8c). These findings are consistent with earlier research by Heeral[24] and Girish Babu[26].

The existence or lack of voids also has a significant impact on how well obturation works. Void creation may

result from procedural errors, canal moisture, and the viscosity of the obturating substance.[24] Pro-AF Baby had the lowest void in this research (Fig. 8e), Kedo S Square, and Kedo SH (Fig. 8d) followed by K-Files. The presence of voids varied statistically significantly across all groups. Compared to hand files (Kedo-SH and hand K-Files), rotary files (Pro AF Baby and Kedo S Square) produced fewer voids. The findings of Vaishali Naidu et al[27] were similar.

Pro AF Baby detected the fewest voids, followed by Kedo S Square, Kedo SH, and K-files. Consequently, there was a notable difference in obturation quality between hand and rotary files.

In the current study, rotary files performed better at cleaning and filling canals than manual files. Clinical and statistical data were considered noteworthy based on more dependable results from rotary files, which showed that Kedo-S 'Square' shortened instrumentation time and that Pro AF Baby had the best-filled canals. Therefore, it can be claimed that use of rotary files produced excellent obturations in a short amount of chairside time.

Only after a week success was assessed in the current study by looking at radiographic and clinical results. Larger longitudinal controls and more volumetric and microscopic evaluations, however, might provide a wider viewpoint for improving the current study and accumulating more data.

**Financial Disclosure:** Nil.

**Conflict of Interest:** None declared.

**Use of AI for Writing Assistance:** No AI technologies utilized.

## References

1. Attari N, Roberts JF. Restoration of primary teeth affected by early childhood caries. *Eur J Paediatr Dent* 2004;5(2):92-7.

2. American Academy of Pediatric Dentistry Clinical Affairs Committee--Pulp Therapy Subcommittee; American Academy of Pediatric Dentistry Council on Clinical Affairs. Guideline on pulp therapy for primary and young permanent teeth. *Pediatr Dent* 2005;27(7 Suppl):130-4.
3. Ochoa-Romero T, Mendez-Gonzalez V, Flores-Reyes H, Pozos-Guillen AJ. Comparison between rotary and manual techniques on instrumentation duration and obturation times in primary teeth. *J Clin Pediatr Dent* 2011;35(4):359-63.
4. Jamali Z, Najafpour E, Ebrahim Adhami Z, Sighari Deljavan A, Aminabadi NA, Shirazi S. Does the length of dental procedure influence children's behavior during and after treatment? A systematic review and critical appraisal. *J Dent Res Dent Clin Dent Prospects* 2018;12(1):68-76.
5. Silva LA, Leonardo MR, Nelson-Filho P, Tanomaru JM. Comparison of rotary and manual instrumentation techniques on cleaning capacity and instrumentation time in deciduous molars. *J Dent Child (Chic)* 2004;71(1):45-7.
6. Mohamed RH, Abdelrahman AM, Sharaf AA. Evaluation of rotary file system (Kedo-S-Square) in root canal preparation of primary anterior teeth using cone beam computed tomography (CBCT)-*in vitro* study. *BMC Oral Health* 2022;22(1):13.
7. Govinda GL, Jeevanandan G, Subramanian EMG. Comparison of quality of obturation and instrumentation time using hand files and two rotary file systems in primary molars: A single-blinded randomized controlled trial. *Eur J Dent* 2017;11(3):376-9.
8. Rathin N, Jain SA, Thosar N, Baliga S, Ahmed F, Mehta J. Comparative evaluation of cleaning efficiency and apical extrusion of debris using two pediatric rotary endodontic files: An *in vitro* study. *Int J Clin Pediatr Dent* 2021;14(2):196-200.
9. Gomes LA, Oliveira AA, de Campos Neves AT, Aranha AM, Volpato LE. Technology incorporation in primary teeth endodontics: Case reports. *Int J Clin Pediatr Dent* 2020;13(2):180-5.
10. Matherne RP, Angelopoulos C, Kulild JC, Tira D. Use of cone-beam computed tomography to identify root canal systems *in vitro*. *J Endod* 2008;34(1):87-9.
11. Coll JA, Sadrian R. Predicting pulpectomy success and its relationship to exfoliation and succedaneous dentition. *Pediatr Dent* 1996;18(1):57-63.
12. Finn S.B. Morphology of primary teeth. In Finn SB, ed. *Clinical Pedodontics*. 4<sup>th</sup> ed. Philadelphia: Saunders Company; 1973. pp. 59-70.
13. Brar GS, Bajaj N, Bhola M, Brar JK. Clinical evaluation of root resorption and its correlation with obturation quality in pulpectomized deciduous teeth with different obturating materials: An *in vivo* study. *Contemp Clin Dent* 2019;10(2):243-8.
14. Bharuka SB, Mandroli PS. Single- versus two-visit pulpectomy treatment in primary teeth with apical periodontitis: A double-blind, parallel group, randomized controlled trial. *J Indian Soc Pedod Prev Dent* 2016;34(4):383-90.
15. Nurko C, Ranly DM, García-Godoy F, Lakshmyya KN. Resorption of a calcium hydroxide/iodoform paste (Vitapex) in root canal therapy for primary teeth: a case report. *Pediatr Dent* 2000;22(6):517-20.
16. Kuo CI, Wang YL, Chang HH, Huang GF, Lin CP, Li UM, et al. Application of Ni-Ti Files for pulpectomy in primary molars-method and short term clinical results. *J Dent Sci* 2006;1:10-11.
17. Jeevanandan G. Kedo-S Paediatric Rotary Files for Root Canal Preparation in Primary teeth - Case report. *J Clin Diagn Res* 2017;11(3):ZR03-5.
18. Yadav A, Burman A, Dighraskar C, Surana P, Dumne SL, Prem M. Pediatric rotary files: The new era of pediatric dentistry. *Int J Dent Sci* 2021;3(1):54-7.
19. Pitchiah P, Shivashankarappa P. Rotary files in pediatric dentistry: From then till now. *J Sci Dent* 2020;10(2):55-7.
20. Makarem A, Ravandeh N, Ebrahimi M. Radiographic assessment and chair time of rotary instruments in the pulpectomy of primary second molar teeth: A randomized controlled clinical trial. *J Dent Res Dent Clin Dent Prospects* 2014;8(2):84-9.
21. Jeevanandan G, Govindaraju L. Clinical comparison of Kedo-S paediatric rotary files vs manual instrumentation for root canal preparation in primary molars: A double blinded randomised clinical trial. *Eur Arch Paediatr Dent* 2018;19(4):273-8.
22. Panchal V, Jeevanandan G, Subramanian E. Comparison of instrumentation time and obturation quality between hand K-file, H-files, and rotary Kedo-S in root canal treatment of primary teeth: A randomized controlled trial. *J Indian Soc Pedod Prev Dent* 2019;37(1):75-9.
23. Govindaraju L, Jeevanandan G, Subramanian E. Clinical Evaluation of Quality of Obturation and Instrumentation Time using Two Modified Rotary File Systems with Manual Instrumentation in Primary Teeth. *J Clin Diagn Res* 2017;11(9):ZC55-8.
24. Shah HS, Patil VM, Kamath AP, Mathur AA. Comparative Evaluation of Instrumentation Time, Obturation Time, and Radiographic Quality of Obturation Using Two Rotary Systems and Manual Technique for Primary Molar Pulpectomies - *In vivo* Study. *Contemp Clin Dent* 2021;12(1):55-62.
25. Govindaraju L, Jeevanandan G, Subramanian E. Knowledge and practice of rotary instrumentation in primary teeth among indian dentists: A questionnaire survey. *J Int Oral Health* 2017;9:45-48.
26. Girish Babu KL, Hebbar KG, Doddamani GM. Correlation between quality of obturation and outcome of pulpectomized primary molars following root canal instrumentation with pediatric rotary file systems. *Pediatr Dent J* 2024;34(1):27-34.
27. Vaishali Naidu D, Sharada Reddy J, Patloth T, Suhasini K, Hema Chandrika I, Shaik H. Cone-beam Computed Tomographic Evaluation of the Quality of Obturation Using Different Pediatric Rotary File Systems in Primary Teeth. *Int J Clin Pediatr Dent* 2021;14(4):542-547.