



Gnathic Desmoplastic Fibroma of the Pediatric Demographic: An Immunohistochemical perspective - A Case report with Review

Raja Raghu¹ Vikas Jha² Mrinalini Rathore¹ Purnima Paliwal³

¹Department of Pedodontics and Preventive Dentistry, Oral Health Sciences Centre, Postgraduate Institute of Medical Education and Research, Chandigarh, India

²Department of Dentistry, Oral and Maxillofacial Surgery, Dr. Ram Manohar Lohia Hospital, New Delhi, India

³Department of Histopathology, Dr. Ram Manohar Lohia Hospital, New Delhi, India

Address for correspondence: Raja Raghu, MDS, Department of Pedodontics and Preventive Dentistry, Oral Health Sciences Centre, Postgraduate Institute of Medical Education and Research, 160012 Chandigarh, India

E-mail: raja.ragu.spm@gmail.com

Abstract

Desmoplastic fibroma is a rare, benign, locally aggressive, intra-osseous tumor that commonly involves the mandible, with a high recurrence rate. A four-year-old boy with a history of painless right mandibular expansion associated with progressive trismus over a period of 18 months was taken up for hemimandibulectomy. The excised lesion was finally diagnosed as desmoplastic fibroma upon histopathological and immunohistochemical assessment. We present the report of the case accompanied by a review of pediatric cases of gnathic desmoplastic fibroma and their immunohistochemistry.

Keywords: Desmoplastic fibroma, hemi-mandibulectomy, immunohistochemistry, intra-osseous tumor, pediatric

Introduction

Desmoplastic fibroma (ICD-O code 8823/0) is a rare, benign, albeit locally aggressive, intra-osseous neoplasm that was first described as a distinct entity from other intraosseous fibrous tumors in 1958 by Jaffe. [1,2] With an estimated incidence of 0.1% of all primary bone tumors, DF may involve any bone but is most frequent in the mandible (22%), followed by the femur (15%), pelvic bones (13%), radius (12%), and tibia (9%). [1] Woods et al [2] reviewed the literature on DF and found a total of 152 reported cases of gnathic DF in an age range of 6 months to 60 years.

Gnathically, mandibular involvement is most common (84%), with a definite predilection for the posterior location in either jaw. [2]

The diagnosis of DF is based on a combination of clinical, radiological, and histopathological features. Immunohistochemical (IHC) analysis has been highlighted as a potential tool to distinguish these lesions from their differentials and in determining prognosis. [3,4] Although most gnathic lesions are painless and slow-growing, these lesions are often locally destructive, with a high recurrence potential. [2] Pediatric cases warrant special consideration of future growth of the face while

How to cite this article: Raghu R, Jha V, Rathore M, Paliwal P. Gnathic Desmoplastic Fibroma of the Pediatric Demographic: An Immunohistochemical perspective - A Case report with Review. J Pediatr Dent 0000;00(0):1-6



planning the surgical extent of excision. We describe one such locally aggressive case of DF in a four-year-old child and its surgical management.

Case Report

A four-year-old boy reported to the Oral and Maxillofacial Outpatient Department with the complaint of a gradually growing, painless swelling over his right lower jaw for the past 18 months, causing progressive restriction of his mouth opening (Fig. 1). He did not report a history of any other systemic illness, hospitalization, or long-term medication. Upon clinical examination, the palpable mass was firm, non-tender, and diffuse, extending from the right submandibular region to the mid-cheek region supero-inferiorly and from the posterior border of the mandible to the angle of the mouth antero-posteriorly. Intraoral assessment was not possible as the child's mouth opening was restricted to less than a finger breadth.

Contrast-enhanced computed tomography (CECT) of the region revealed a soft tissue expansile mass in the right submandibular region measuring about 3.9 cm (AP) × 4.5 cm (TR) on axial image and 3.5 cm (SI) on coronal image (Fig. 2). The mass caused posterior displacement of the submandibular gland; however, there was a distinct fat plane between the two. Medially, it compressed the floor of the mouth. Computed tomography (CT) images showed erosion and destruction of the angle and body of the mandible and the mentum. Signs of bony remodeling of the right side of the mandible were also evident.

Segmental resection of the mandible, followed by reconstruction using reconstruction plates under general anesthesia (GA), was planned for the patient. Through a right submandibular incision, a layer-by-layer dissection was done to expose the tumor mass, and a right segmental mandibulectomy including the coronoid process while sparing the condyle was performed. A margin of about one centimeter was secured in normal tissue following excision, and reconstruction was done with a recon plate (Fig. 2c, d). The sectioned tissue was stored in 10% formaldehyde and sent for histopathological analysis.

Upon processing the excised tissue, a firm fibrous whorled mass measuring 4×3×2.5 cm was identified. Microscopically, sections showed a hypocellular spindle cell tumor with bland spindle-to-stellate cells arranged haphazardly against a collagenous background (Fig. 3a, b). These cells showed ill-defined cytoplasmic outlines, pale vesicular nuclei with mild anisonucleosis, and inconspic-

uous nucleoli. Mitotic activity was inconspicuous, and many capillary channels were interspersed. No atypia, necrosis, or mitosis was reported. No odontogenic epithelium, calcification, or bony trabeculae were identified, thus ruling out odontogenic fibroma and fibrous dysplasia.

Histologic differential diagnoses of solitary fibrous tumor and desmoplastic fibroma were considered, and immunohistochemical (IHC) markers were applied. IHC staining showed focal positivity for vimentin, cytoplasmic SMA (smooth muscle actin), and beta-catenin, and negativity for S100 and CD34 (Fig. 4a-d). Thus, IHC findings confirmed a diagnosis of desmoplastic fibroma.

Clinically, the surgery restored the child's mouth opening (Fig. 5), and no recurrence was noted after two years of follow-up. The parents were counseled about the need for regular follow-up and further interventions as the child grows.

Discussion

Desmoplastic fibroma (DF) is regarded as the morphological bony counterpart of desmoid-type fibromatosis and most commonly affects the mandible (~40% of all bony sites), followed by the femur and pelvis.[2] Recurrence following curettage and resection is reported as ~72% and ~17%, respectively.[2] Solitary or multiple desmoid lesions have also been found in association with conditions like tuberous sclerosis and Gardner syndrome.[4,5] About 84% of gnathic DF cases are found in individuals aged less than 30 years, with a mean age of 16 years.[2]

Considering the vast sea of pathologies manifesting as painless, expansile swellings of the pediatric jaws, a di-

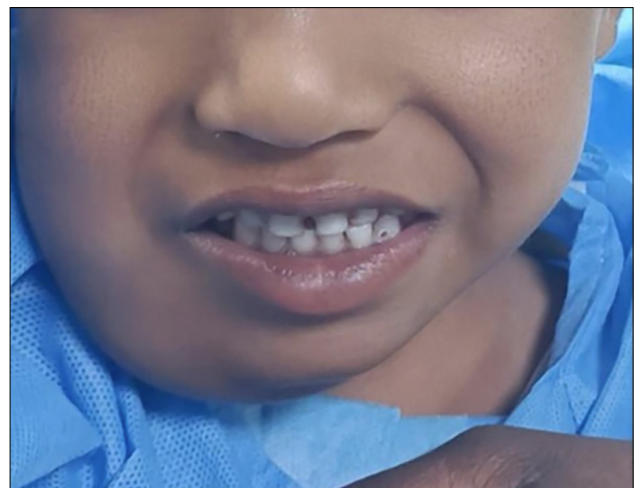

Figure 1. Pre-operative extra-oral image

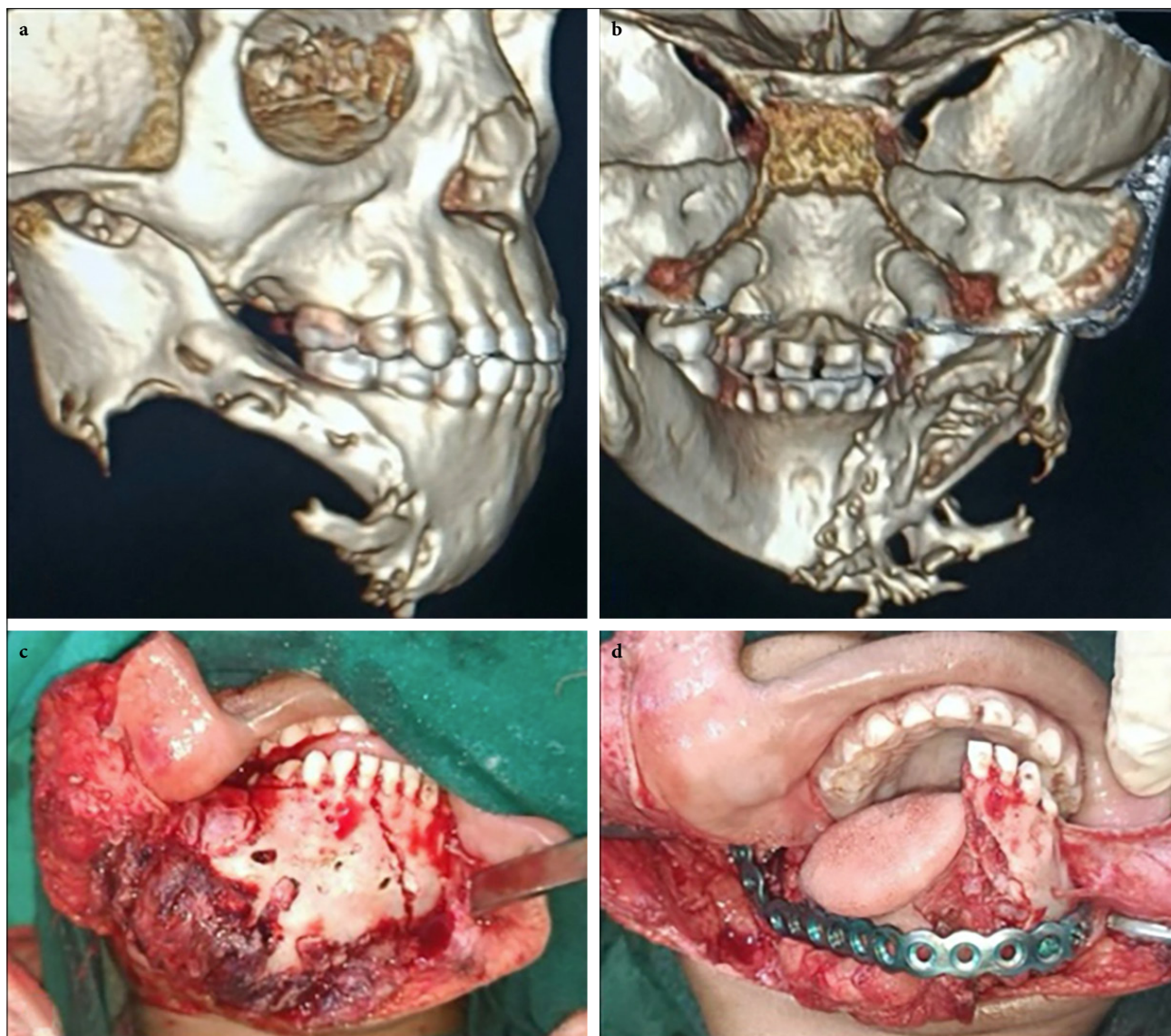


Figure 2. (a, b) Pre-operative three dimensional CBCT image of affected mandible; (c&d) Intra-operative images
CBCT: Cone-beam computed tomography

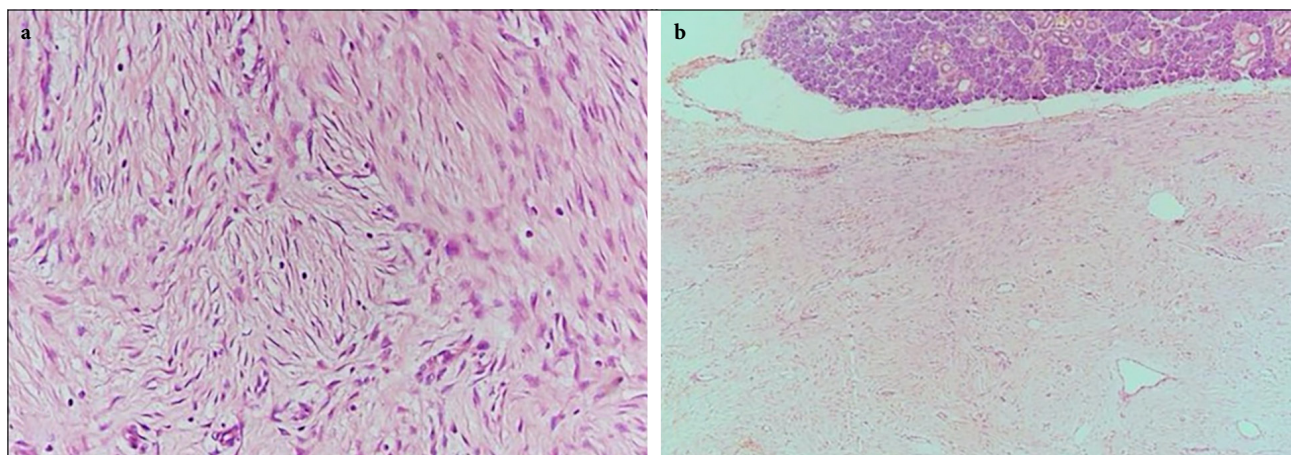


Figure 3. Histopathological images (a) H&E x40; (b) H&E x100

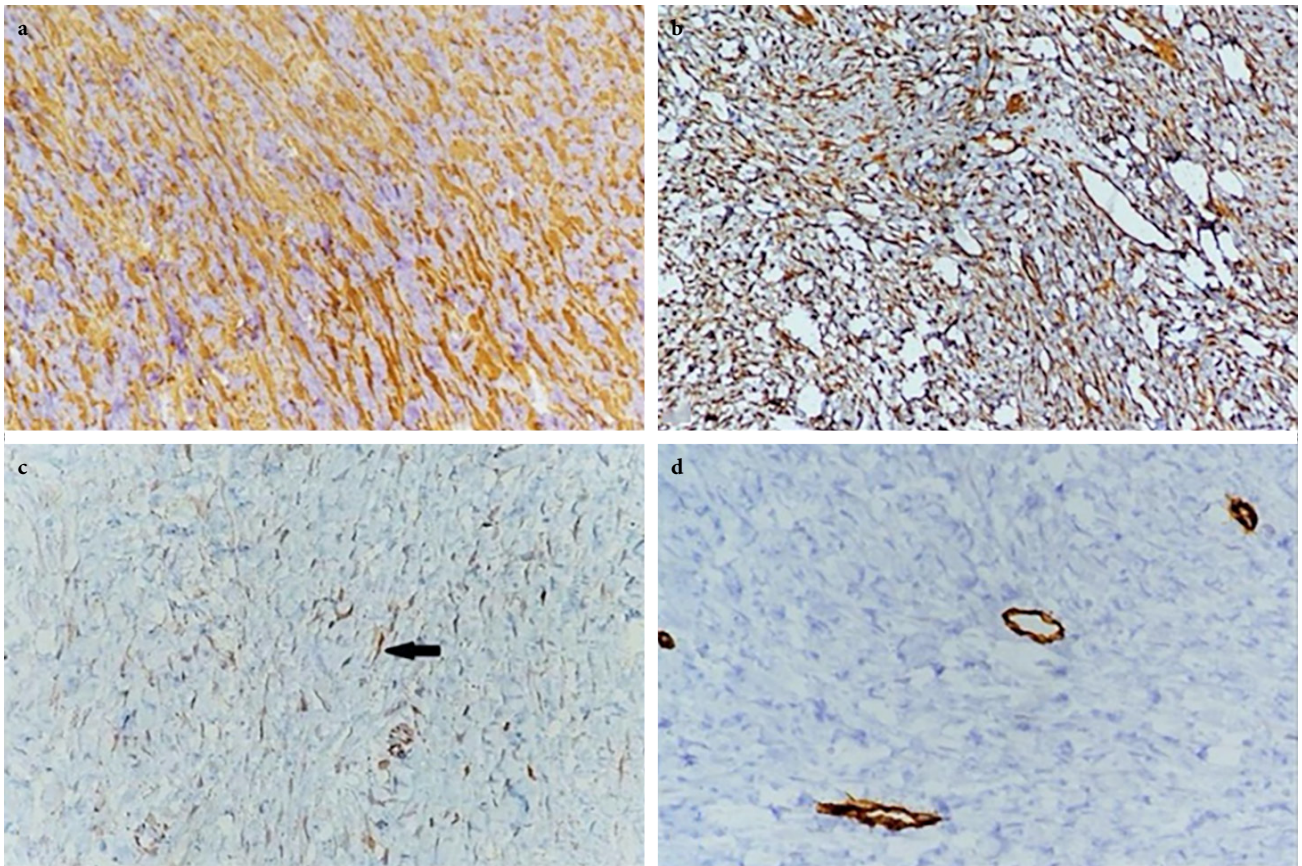


Figure 4. Immunohistochemistry staining (a) Diffuse cytoplasmic immunoreactivity for Vimentin (Vimentin×400); (b) Diffuse strong immunoreactivity for SMA (SMA×100); (c) Diffuse strong focal nuclear immunoreactivity for Beta-catenin (β -catenin×400); (d) CD 34 negative in tumor cells, strong positivity in blood vessels (CD34×400)

SMA: Smooth muscle actin, CD: Cluster of differentiation

agnosis of DF is confirmed by correlating the clinical and radiological picture with an astute histological examination supported by immunohistochemistry of the tissue. The World Health Organization defines the histological criteria for desmoplastic fibroma as that of a benign tumor of low to variable cellularity, whose cells can be ovoid or elongated with uniform nuclei that lack atypia, pleomorphism, and mitotic activity.[2]

A literature search was made using MESH terms “Desmoplastic fibroma,” “child*,” “mandible OR maxilla” in the PubMed database. Twenty-six reports of gnathic DF occurring in children under 15 years were thus identified and compared (Table 1). Twenty-three of those were reported in the mandible, with the majority occurring in the posterior mandible. The youngest child reported to have a gnathic DF was an infant aged 6 months.[6] Recurrence or persistence of lesions was reported in three cases, all of which had received a relatively conservative initial treatment with either local excision or chemotherapy.[7–9] The majority were treated with complete or partial mandibulectomies or segmen-

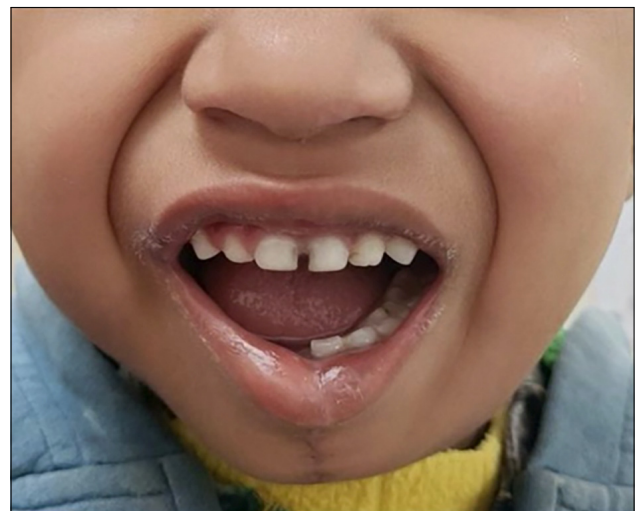

Figure 5. One month post-operative extra-oral image with significant improvement in the mouth opening

tal resections. The final diagnosis of DF was established based on histological reports consistent with the criteria defined by the World Health Organization (WHO).[2]

Table 1. Characteristics of Paediatric cases of Gnathic DF in literature

Author & year	Age/gender	Site/size	Treatment	Immunohistochemistry	Follow up; Recurrence
Said-Al-Natef et al[1]	8/M	Right mandible	Mandibular Inferior Border resection	NA	4-5 years; Nil
Woods et al[2]	13/M	Right mandible	Marginal resection	Positive labelling: SMA, Vimentin, HHF-35/ muscle specific actin. Negative reactivity: β -catenin and S-100, Ki-67 < 1 %.	3-5 years; Nil
Madakshira MG et al[3]	5/M	Right mandible	Excision	Cytoplasmic positivity for vimentin and smooth muscle actin. Negative for β -catenin	5 mo; Nil
Vargas Gonzale et al[5]	14/M	Left Maxilla	Resection	NA	NA
Wippold FJ et al[6]	6mo/M	Right mandible	Hemimandibulectomy	NA	NA
Summa et al[7]	3/F	Right Mandible	Excision	NA	NA; Recurrence reported, treated with Chemotherapy
Flucke et al[8]	8/F 2/M	Mandible Mandible	Excision Resection	Nuclear β -catenin positivity	3 years; Slow progression
Karimi A et al[9]	2/F	Right mandibular angle	Segmental Mandibulectomy	Nuclear β -catenin positivity	13 years; Nil
Iatrou IA, et al[10]	10/M	Left mandibular angle	Peripheral ostectomy	Strongly positive nuclear immunoreactivity for β -catenin. Mild positive staining for α -SMA	8 mo; Nil
Motevasseli S, et al[11]	5/M	Right Mandible	Resection	Fibroblasts showed positive results for Vimentin and S-100 protein antibodies	5 years; Nil
Khatib B, et al[12]	8/F	Left mandible	Left mandibulectomy	Positive for Vimentin (cytoplasmic) and β -catenin (Diffuse cytoplasmic, focal nuclear)	14 mo; Nil
	4/F	Left posterior mandible	Resection	NA	14 year; Nil
	2/M	Left Mandibular angle	Segmental resection	NA	13 years; Nil
Cupero, et al[13]	2/F	Right Mandibular ramus extending into infratemporal fossa	Chemotherapy (discontinued after 12 mo)	NA	12 years; Nil
	14/F	Right maxilla extending through orbital floor	Right maxillectomy with orbital preservation	NA	6 years; Tumor persisted without progression
Herford, et al[14]	11/F	Right mandibular angle	Marginal Mandibulectomy	NA	48 mo; None
Kaplan, et al[15]	3/M	Right mandible	NA	NA	NA
Sandrini, et al[16]	11/M	Left mandibular angle	Excision	NA	NA
Ferrri, et al[17]	3/F	Right mandible	Partial right mandibulectomy	NA	33mo; Nil
	2/F	Left mandible	Partial left mandibulectomy	NA	36 mo; Nil
	2/F	Right mandible	Right mandibular resection	NA	26 mo; Nil
Gersak MM, et al[18]	3/M	Right mandible	Right mandibular resection	NA	17 years; Nil
	3.7/M	Right mandible	Right mandibulectomy and reconstruction with osseous free fibula flap	NA	NA
Mohammadi, et al[20]	2/M	Right Mandible (Recurrent lesion after previous enucleation < 12mo ago)	Segmental mandibulectomy	Strong immunoreactivity for Vimentin and β -catenin. Non reactive with S-100 and desmin.	6 years; Nil
					18 mo; Nil

M: Male, F: Female, NA: Not applicable

Immunohistochemistry was reported in eight cases, and they expressed variable positivity for vimentin, SMA, desmin, cytoplasmic β -catenin, and nuclear β -catenin. [2,3,8–10] Desmoid-type soft tissue fibromatosis has been shown to express nuclear and cytoplasmic β -catenin positivity.[4,8] However, the consistency of their expression in the intra-osseous counterparts is uncertain. Kahraman et al[4] reported positive expression of cytoplasmic β -catenin in more than half of their 22 cases, but none with nuclear β -catenin positivity. Meanwhile, Flucke et al[8] reported nuclear β -catenin positivity in all seven of the cases in their case series. Our search identified five reports of pediatric gnathic DF with positive nuclear β -catenin expression similar to our case. Unfortunately, very few authors reported the IHC characteristics of the excised lesions.

Motevasseli et al[11] discussed a periosteal reaction in the mandibular inferior border as a sign of DF in its initial stages; it evaded surgical treatment at its incipient stage due to nonspecific histological findings.

Conclusion

The case went on to grow aggressively, as is typical of DF, eventually warranting hemimandibulectomy. With nonspecific clinical and radiological presentations and the wide spectrum of histologically similar pathologies affecting the jaws, immunohistochemistry should be considered an essential tool in diagnosing these locally aggressive lesions, thus avoiding demolitive interventions at advanced stages. Therefore, standardized protocols for IHC analysis and reporting in the literature need to be developed and enforced.

The authors also feel the need for longitudinal studies highlighting patient outcomes in such conditions.

Financial Disclosure: Nil.

Conflict of Interest: None declared.

Use of AI for Writing Assistance: No AI technologies utilized.

References

- Said-Al-Naief N, Fernandes R, Louis P, Bell W, Siegal GP. Desmoplastic fibroma of the jaw: a case report and review of literature. *Oral Surg Oral Med Oral Pathol Oral Radiol Endod* 2006;101(1):82–4.
- Woods TR, Cohen DM, Islam MN, Rawal Y, Bhattacharyya I. Desmoplastic fibroma of the mandible: a series of three cases and review of literature. *Head Neck Pathol* 2015;9(2):196–204.
- Madakshira MG, Bal A, Verma RK. Desmoplastic fibroma of the mandible: a rare gnathic bone tumor with a review of the literature. *Autops Case Rep* 2019;9(4):e2019091.
- Kahraman D, Karakoyunlu B, Karagece U, Ertas U, Gunhan O. Desmoplastic fibroma of the jaw bones: a series of twenty-two cases. *J Bone Oncol* 2020;26:100333.
- Vargas-Gonzalez R, San Martin-Brieke W, Gil-Orduña C, Lara-Hernandez F. Desmoplastic fibroma-like tumor of maxillo-facial region associated with tuberous sclerosis. *Pathol Oncol Res* 2004;10(4):237–9.
- Wippold FJ 2nd, White FV, Jamroz G, Haughey B, Forsen J. Desmoplastic fibroma of the mandible in an infant. *Pediatr Radiol* 2005;35(9):906–9.
- Summa A, Cerasti D, Crisi G, Ormitti F, Ventura E, Sabato M. Desmoplastic fibroma of the mandible: usefulness of CT and MR imaging in diagnosis and treatment. A case report. *Neuroradiol J* 2010;23(1):109–13.
- Flucke U, Tops BB, van Diest PJ, Slootweg PJ. Desmoid-type fibromatosis of the head and neck region in the paediatric population: a clinicopathological and genetic study of seven cases. *Histopathology* 2014;64(6):769–76.
- Karimi A, Derakhshan S, Moradzadeh Khiavi M, Mosavat F, Mirjalili F. Desmoplastic fibroma of the jaws: a case series and review of literature. *Iran J Pathol* 2020;15(2):134–43.
- Iatrou IA, Theologie-Lygidakis N, Leventis MD. Case report: desmoplastic fibroma of the mandible in a child presenting with TMJ dysfunction. *Eur Arch Paediatr Dent* 2008;9(2):105–8.
- Motevasseli S, Yousefi Z, Dalili Kajan Z, Modanlou R, Roudbari N. Periosteal reaction as a crucial radiographic finding for desmoplastic fibroma of the jaw bone in children: a case report. *Imaging Sci Dent* 2022;52(3):319–26.
- Khatib B, Pogrel MA. Desmoplastic fibroma of the mandible in young children—a case series. *Int J Oral Maxillofac Surg* 2017;46(2):173–80.
- Cupero TM, Thomas RW, Manning SC. Desmoplastic fibroma of the maxillary sinus. *Otolaryngol Head Neck Surg* 2001;125(6):661–2.
- Herford AS, Reder P, Ducic Y. Multifocal desmoplastic fibromas of the mandible. *J Oral Maxillofac Surg* 2001;59(9):1078–81.
- Kaplan KJ, Torske KR. Pathologic quiz case: a 3-year-old boy with swelling of the right mandible. *Arch Pathol Lab Med* 2002;126(1):107–8.
- Sandrini FA, do Egito Vasconcelos BC, Bessa-Nogueira RV. Desmoplastic fibroma of mandible in a child: case report. *Indian J Surg* 2007;69(6):254–6.
- Ferri A, Loporati M, Corradi D, Ferri T, Senna E. Huge desmoplastic fibroma of the paediatric mandible: surgical considerations and follow-up in three cases. *J Craniomaxillofac Surg* 2013;41(5):367–70.
- Gersak MM, Lenghel LM, Baciut G, Moldovan I, Mitea H, Botar-Jid C, Vasilescu D, Boțan E, Duda SM. Ultrasonography of desmoplastic fibroma of the mandible: a case report. *Med Ultrason* 2015;17(3):407–10.
- Skinner HR, Vargas A, Solar A, Fonca C, Astorga P. Desmoplastic fibroma of the mandible in a pediatric patient: a case report of resection and reconstruction with a six-year follow-up. *J Oral Maxillofac Surg* 2017;75(7):1568.e1–1568.e10.
- Mohammadi F, Shirani G, Derakhshan S, Faghihi T. Desmoplastic fibroma of the lower jaw in a 2-year-old patient: report of a rare case. *Dent Res J (Isfahan)* 2020;17(3):231–4.