



# An Accessory Cusp and Three-rooted Deciduous Mandibular First Molar: A Rare Entity

Nur Iryani Izzaty Andytan<sup>1</sup> Nur Fara Izani Ikhwan<sup>1</sup> Alaa Sabah Hussien<sup>2</sup> Siti Hajar Hamzah<sup>2,3</sup>  
Mas Suryalis Ahmad<sup>4</sup>

<sup>1</sup>Oral Health Division, Ministry of Health, Putrajaya, Malaysia

<sup>2</sup>Centre of Paediatric Dentistry and Orthodontics Studies, Faculty of Dentistry, Universiti Teknologi MARA, Selangor, Malaysia

<sup>3</sup>Faculty of Dentistry, National University of Singapore, Singapore

<sup>4</sup>Centre of Comprehensive Care Studies, Faculty of Dentistry, Universiti Teknologi MARA, Selangor, Malaysia

**Address for correspondence:** Siti Hajar Hamzah, BDS, PhD, Centre of Paediatric Dentistry and Orthodontics Studies, Faculty of Dentistry, Universiti Teknologi MARA, Sungai Buloh Campus, Sungai Buloh, Selangor, Malaysia

**E-mail:** shajarhamzah1998@gmail.com

## Abstract

This case report describes the management of a 6-year-old boy who presented with bilateral deciduous first molars (74 and 84) that contained accessory cusps, with tooth 74 also having three roots. Non-cavitated dentinal caries on both teeth were restored with stainless steel crowns, along with a personal and professional preventative oral health care regimen that included fluoride therapy and frequent recall. The case highlights the importance of performing a thorough investigation, acquiring a sound knowledge of tooth anomalies and root morphology, and demonstrating radiographic interpretation skills to allow for the identification of oral conditions and the development of diagnoses. In addition, the case also discusses factors to consider when developing a treatment plan aimed at improving a patient's treatment outcome and long-term prognosis.

**Keywords:** Accessory cusp, additional roots, dental anomalies, primary mandibular first molar, three-rooted

## Introduction

Human dentitions may show variations in morphological structures that present in the form of anomalous cusps or an increased number of roots.[1] Accessory cusps are one of the anomalies that sometimes occur in the deciduous dentition due to abnormal proliferation of the epithelial fold during the differentiation phase of tooth development.[1] On the other hand, the presence of a three-rooted deciduous mandibular first molar, although a relatively rare occurrence, has also been reported and is found primarily on a unilateral site.[2]

Three-rooted permanent mandibular first molar and primary mandibular second molar are a common finding and widely reported in the literature, however, the presence of three-rooted primary mandibular first molar is relatively rare with only a few cases being reported.[3] Although its presentation is uncommon, the highest incidence rate is reported in people of Mongolian origin namely Japanese, Malaysian, Chinese, Thai, Eskimo, Aleutian, and American Indian.[4] It is the typical presentation was described as primarily unilateral.[5]

The literature to date has not yet reported the finding of a single deciduous mandibular first molar, with

**How to cite this article:** Andytan NI, Ikhwan NF, Hussien AS, Hamzah SH, Ahmad MS. An Accessory Cusp and Three-rooted Deciduous Mandibular First Molar: A Rare Entity. J Pediatr Dent 2023;9(1):00-00

**OPEN ACCESS** This work is licensed under a Creative Commons Attribution-NonCommercial 4.0 International License.



three roots and an accessory cusp. This case report, however, presents the incidental clinical finding of this rare occurrence and its clinical management. It highlights the necessity of performing a thorough investigation while having a sound knowledge of root canal morphology and systems of the deciduous dentition. In addition, the case also discusses the importance of personal and professional preventative care for patients with high caries risk, including the need for regular review, to ensure effective control of oral disease and maintenance of oral health.

## Case Report

A 6-year-old boy came to the pediatric dentistry clinic at Universiti Teknologi MARA for a regular dental review. He had no medical illness, and the patient was not on any medications or supplements. The patient practiced twice daily toothbrushing using fluoridated toothpaste formulated for children. No significant findings were noted from his family and social history, including his dietary intake and parafunctional habits. His last dental check-up was 6 months ago, where he received prophylactic cleaning, followed by restorative treatment with composite material on six cavitated teeth.

A general examination revealed that his height and weight were within normal limits for his age. The extraoral examination was unremarkable (symmetrical face, competent lip, normal mouth opening, and impalpable submandibular lymph nodes).

Intraoral examination found non-cavitated lesions with visible underlying dark dentine shadow on the distal surfaces of teeth 74 and 84. An accessory cusp was also noted on the occlusal surface of both teeth (Fig. 1). No caries was clinically noted on other teeth. His oral hygiene status was good (plaque score, 15%).

Investigation with periapical (PA) radiographs was carried out to assess the extension of caries on teeth 74 and 84. PA radiograph of tooth 84 showed an area of radiolucency on the distal tooth surface that extended to dentine, with the presence of an additional pulp horn (Fig. 2a). The PA radiograph of tooth 74 showed evidence of an additional root, area of radiolucency on the distal tooth surface that extended to dentine, and the presence of an additional pulp horn (Fig. 2b).

Teeth 74 and 84 were each treated with the placement of a stainless-steel crown (Fig. 3). Other treatment methods included dental prophylactic cleaning and full-mouth fluoride varnish application. The patient

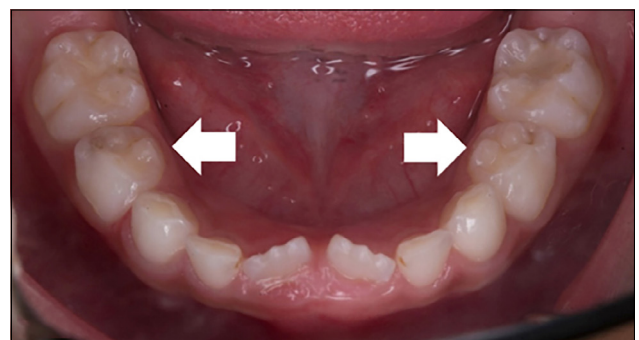
was also given oral hygiene instruction in the presence of his parents, and a 3-month review was scheduled for maintenance.

## Discussion

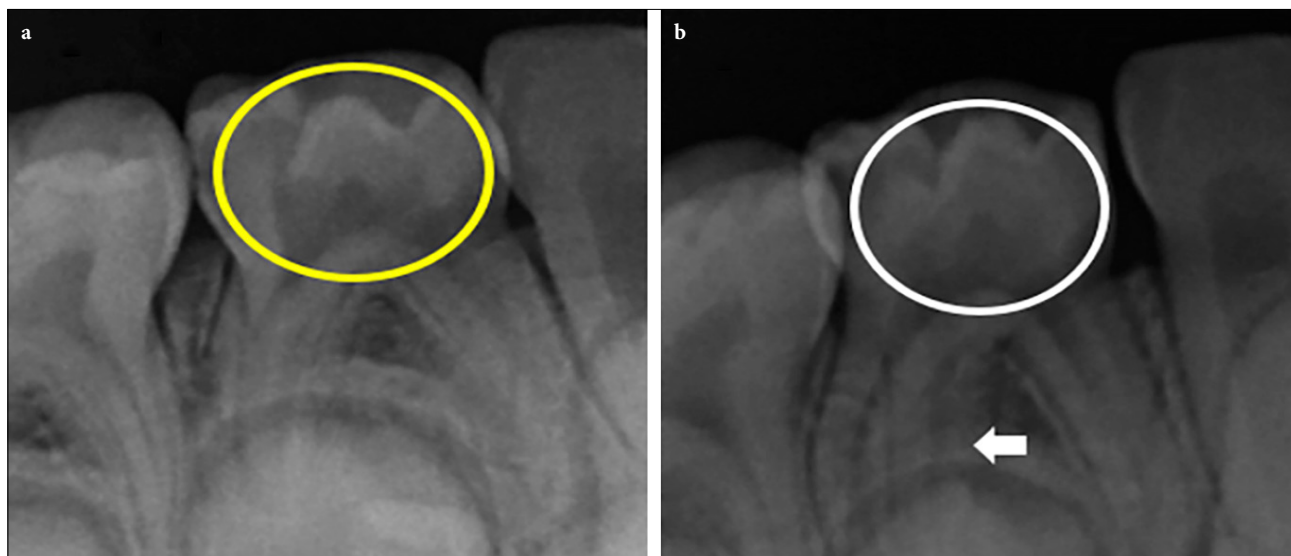
This case reports the rare occurrence of a primary first mandibular molar (tooth 74) with three roots and an accessory cusp, a condition which has not previously been reported. The presentation of such anomalies is consistent with previous findings that separately reported the occurrence of an accessory cusp and three-rooted deciduous mandibular first molar in people of Asian descent.[1,2]

The case also highlights the need for regular review and monitoring of patients, despite the absence of signs and symptoms. This is to avoid the progression of the disease to a more severe state, such as that presented in this case, should the underlying dark dentine shadow not be detected. The presence of an accessory cusp may further accelerate the formation of caries, as it allows plaque retention, especially in the pits or developmental grooves between the accessory cusp and the tooth.[6] If not appropriately managed, the caries may continue to progress, requiring more complex treatment or resulting in the early loss of deciduous teeth.[7] Therefore, regular review is important to ensure that any oral health and dental issues are detected early and managed accordingly. Maintenance of oral health and management of oral diseases in pediatric patients is crucial to allow for the healthy formation and eruption of permanent teeth,[8] and thus must be emphasized at every developmental stage of a child.

This case highlights the importance of undertaking a thorough oral health investigation and acquiring a sound knowledge of root canal morphology of deciduous



**Figure 1.** Intraoral occlusal view showing evidence of an accessory cusp located on the occlusal surface of bilateral primary mandibular first molars (white arrows)

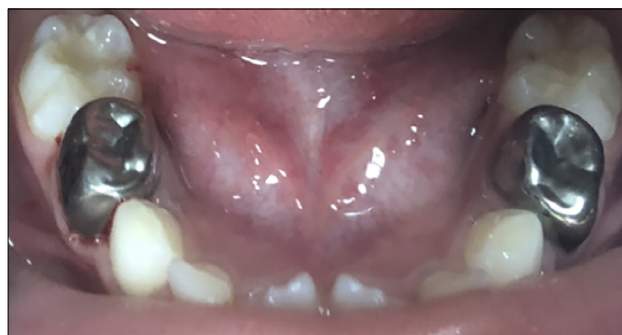

**Figure 2.** (a) Periapical radiograph of right primary mandibular molar showing an area of radiolucency on the distal surface of right primary mandibular first molars and presence of additional pulp horn (yellow circle). (b) Periapical radiograph of left primary mandibular molar showing evidence of an additional root (white arrow) and area of radiolucency on the distal surface of left primary mandibular first molars and presence of additional pulp horn (white circle)

ous teeth. In this case, the presence of the accessory cusps was only noted during a review visit, instead of during the active treatment phase 6 months earlier. Failure to detect this condition may be due to an absence of signs and symptoms affecting both teeth during that time, rendering the teeth exposed to caries development.

To allow for the detection of tooth anomalies, the application of appropriate investigative procedures must be practiced. It was suggested that PA radiographs would provide diagnostic value adequate to detect the presence of an accessory cusp, caries, and PA lesions, as well as to determine the size of the pulp chamber and the shape of roots.[9] Meanwhile, the morphology of the root canal system could be more precisely defined with the use of a more advanced radiographic tool, such as cone-beam computed tomography (CBCT).[10] However, CBCT investigation was not undertaken in this case, as it was deemed to not provide additional value to the diagnosis and treatment plan at that stage. In addition, it was unnecessary to expose the child to CBCT, which has a high dose of ionizing radiation,[11] when the results of the investigation in this case were sufficiently achieved with the use of a peri-apical radiograph.

There are several non-surgical options for treating this non-cavitated carious lesion on these bilateral mandibular first primary molars. Non-surgical treatment options include the use of silver diamine fluoride (SDF) and resin infiltration. The reported success rate



**Figure 3.** Intraoral occlusal view showing stainless steel crown placed on bilateral primary mandibular first molars

of SDF application on mandibular primary molars was 71% and maxillary primary molars was 83–86% among patients treated in the community study. The same articles demonstrated that the success rate of SDF in the low caries risk assessment was 81%, compared to 76% and 75% in the moderate and high caries risk assessments, respectively.[12] Furthermore, a recent published systematic review and meta-analysis found that resin infiltration has a higher success rate in delaying the caries process in non-cavitated proximal carious teeth.[13]

However, the decision to use a stainless-steel crown for this patient’s restorative treatment was made as a preventive measure to avoid food impaction in the deep pits and fissures around the accessory cusp, which could lead to caries later.[14] In addition to avoiding

restorative failures such as filling dislodgement and fracture.[15,16] Stainless-steel crown demonstrated a higher longevity,[15,17] and revealed a seven percent failure rate in 5 years.[15,18] Restorative failure can occur due to an unsupported tooth structure caused by a fractured accessory cusp. Due to occlusal interference caused by premature tooth contact, the accessory cusp may fracture.[19] Tooth sensitivity or devitalization may result from fracture or attrition of the protruded accessory cusp.[20] Taking these factors into account, a stainless-steel crown was chosen due to its superior physical and mechanical properties.[21] Pulp therapy is not indicated in this case due to the lack of radicular pulpitis symptoms and the extent of the caries lesion, which only involved the dentine layer.

While it is important to decide on the proper techniques and materials to manage this condition, long-term maintenance and preventative care should also be thoroughly considered when determining patient treatment plans. Rigorous preventative care is especially important for this patient, who has a high caries risk, given the presence of new carious lesions and his recent history of multiple restorations.[22] The importance of twice daily toothbrushing using fluoridated toothpaste was emphasized, in addition to providing advice to abstain from cariogenic dietary habits, such as snacking behavior.

Although this patient was encouraged to practice daily oral hygiene, professional preventative treatment is also essential for oral disease control. Such care includes professional topical fluoride treatment, which can be delivered through fluoride varnish application. Although the use of professional topical fluoride treatment is not indicated for everyone, its use is recommended for those with high caries risk, which was demonstrated in this particular patient.[16] Frequent recall (every 3 months) was also indicated as important to maintaining oral health, emphasizing positive oral hygiene practices and healthy habits, while allowing for the early detection and management of potential or presenting oral complications.[23]

The presence of additional roots in this case may not provide as much clinical significance as an accessory cusp. However, the identification of such root morphology is important, should the patient require endodontic treatment or exodontia. In terms of normal exfoliation, having an extra root should not cause complications, as the tooth may have undergone root resorption at this stage.[24]

## Conclusion

The presence of an accessory cusp in conjunction with a three-rooted primary mandibular first molar is an unusual occurrence. For developing a diagnosis and planning patient treatment, a thorough clinical examination, as well as sound radiographic knowledge and interpretation skills, are critical. Frequent review, along with a well-executed personal and professional oral health preventive care plan, is critical to ensuring effective disease control and oral health maintenance.

**Acknowledgments:** The authors wish to acknowledge the patient and his parent for providing us with their consent to have the case published and presented for educational purpose.

**Data availability:** The patient's data and treatment details are recorded in the University A electronic system. Access to the data is reserved for registered users only, unless required by law. The patient's record will be kept for 7 years after the last treatment.

**Financial Disclosure:** Nil.

**Conflict of Interest:** None declared.

## References

- Shilpa G, Gokhale N, Mallineni SK, Nuvvula S. Prevalence of dental anomalies in deciduous dentition and its association with succedaneous dentition: A cross-sectional study of 4180 South Indian children. *J Indian Soc Pedod Prev Dent* 2017;35:56–62.
- Gupta S, Nagaveni NB, Chandranee NJ. Three-rooted mandibular first primary molar: Report of three cases. *Contemp Clin Dent* 2012;3:134–6.
- Mokhtari S. Primary mandibular first molar with three reports. *Pakistan Oral and Dent J* 2013;33:74–5.
- Ferraz JA, Pecora JD. Three-rooted mandibular molars in patients of Mongolian, Caucasian and Negro origin. *Braz Dent J* 1992;3:113–7.
- Ming GT, Jeng FL, Pei WD, San YC, Jui TH, Heng LH. Prevalence of three-rooted primary mandibular first molars in Taiwan. *J Formos Med Assoc* 2010;109:69–74.
- Meon R. Talon cusp in Malaysia. *Aust Dent J* 1991;36:11–4.
- Innes NPT, Evans DJP. Managing caries in primary teeth. *BDJ Team* 2014;1:14118.
- Dhamo B, Elezi B, Kragt L, Wolvius EB, Ongkosuwito EM. Does dental caries affect dental development in children and adolescents? *Bosnian J Basic Med* 2018;18:198–205.
- Gupta A, Devi P, Srivastava R, Jyoti B. Intra oral periapical radiography - basics yet intrigue: A review. *Bangladesh J Dent Res Educ* 2014;4:83–7.
- Verma GR, Bhadage C, Bhoosreddy AR, Vedpathak PR, Mehrotra GP, Nerkar AC, et al. Cone Beam Computed Tomography Study of Root Canal Morphology of Permanent Mandibular Incisors in Indian Subpopulation. *Pol J Radiol* 2017;82:371–5.
- Shin HS, Nam KC, Park H, Choi HU, Kim HY, Park CS. Effective doses from panoramic radiography and CBCT (cone beam CT)

- using dose area product (DAP) in dentistry. *Dentomaxillofac Radiol* 2014;43:20130439.
12. Raskin SE, Tranby EP, Ludwig S, Okunev I, Frantsve-Hawley J, Boynes S. Survival of silver diamine fluoride among patients treated in community dental clinics: A naturalistic study. *BMC Oral Health* 2021;21:35.
  13. Elrashid AH, Alshaiji BS, Saleh SA, Zada KA, Baseer MA. Efficacy of resin infiltrate in noncavitated proximal carious lesions: A systematic review and meta-analysis. *J Int Soc Prev Community Dent* 2019;9:211–8.
  14. Chandra B, Das M. Accessory central cusp in the maxillary second primary molars: A rare entity among the rare. *Int J Clin Pediatr Dent* 2014;7:202–5.
  15. American Academy of Pediatric Dentistry. Guideline on restorative dentistry. *Pediatr Dent* 2016;38:250–62.
  16. Hickel R, Kaaden C, Paschos E, Buerkle V, García-Godoy F, Manhart J. Longevity of occlusally-stressed restorations in posterior primary teeth. *Am J Dent* 2005;18:198–211.
  17. Sonmez D, Duruturk L. Success rate of calcium hydroxide pulpotomy in primary molars restored with amalgam and stainless steel crowns. *Br Dent J* 2010;208:18.
  18. Randall RC. Preformed metal crowns for primary and permanent molar teeth: Review of the literature. *Pediatr Dent* 2002;24:489–500.
  19. Chowdhary Z, Gupta D, Mohan R, Bajaj A. Parastyle cusp: A rare morphologic variant of maxillary second molars. *J Forensic Sci* 2018;10:111–5.
  20. Appadurai R, Lingeshwar D, Missier M, Maila S. Permanent mandibular protostylid: A rare developmental anomaly and its overview. *Indian J Dent Res* 2018;29:244–6.
  21. Bamdadian Z, Pasdar N, Alhavaz A, Ghasemi S, Bijani A. Comparative evaluation of physical and mechanical properties of different brands of primary molar stainless-steel crowns: An *in vitro* study. *Open Access Maced J Med Sci* 2019;7:4120–6.
  22. Suneja E, Suneja B, Tandon B, Philip N. An overview of caries risk assessment: Rationale, risk indicators, risk assessment methods, and risk-based caries management protocols. *Indian J Dent Sci* 2017;9:210–4.
  23. American Academy of Pediatric Dentistry. Guideline on caries-risk assessment and management for infants, children, and adolescents. *Pediatr Dent* 2017;39:197–204.
  24. Harokopakis-Hajishengallis E. Physiologic root resorption in primary teeth: Molecular and histological events. *J Oral Sci* 2007;49:1–12.