



Successful Management of Large Dentigerous Cyst with Spontaneous Eruption of Affected Teeth by Minimal Invasive Surgical Approach: A Case Report

Mohammad Kamran Khan¹ Mahendra Kumar Jindal¹

¹Department of Pediatric and Preventive Dentistry, Dr ZA Dental College, Aligarh Muslim University, Aligarh, Uttar Pradesh, India

Address for correspondence: Mohammad Kamran Khan, BDS, MDS, Department of Pediatric and Preventive Dentistry, Dr. Z.A. Dental College and Hospital, Faculty of Medicine, Aligarh Muslim University (A.M.U.), Aligarh-202002, Uttar Pradesh, India
E-mail: mohdkamran0009@gmail.com

Abstract

Dentigerous cysts are rarer to occur in children compared to adult patients. Non-vital deciduous teeth which are associated with dentigerous cysts of inflammatory origin are mostly found in mixed dentition stage. This case report presents a successful management of a large dentigerous cyst that was associated with a grossly carious primary molar which involved multiple unerupted immature permanent teeth of mandible in a 12 years old patient. The procedure which was used for the management was marsupialization. The follow-up evaluation showed complete healing of the cystic lesion, and spontaneous eruption of the involved permanent teeth. It also resulted in complete resolution of facial asymmetry without any recurrence or complications.

Keywords: Dentigerous cyst, large odontogenic cyst, marsupialization, minimal invasive surgery, mixed-dentition, pediatric patient

Introduction

Dentigerous cysts are considered to be one of the most commonly found developmental odontogenic cysts of jaw (25%).^[1,2] Although there is an abundant number of published literature about dentigerous cysts in adults, literature regarding the dentigerous cysts in the pediatric age group is still deficient. Dentigerous cyst is a cystic lesion of odontogenic origin, associated with the crown of the impacted or unerupted tooth. These cysts are believed to develop by the expansion of the tooth follicle due to the collection of fluid between the reduced enamel epithelium (REE) and the enamel sur-

face of the unerupted tooth.^[3] Dentigerous cysts are usually solitary cysts, but multiple cysts in a jaw seldom occur and in those situations, syndromes such as Maroteaux-Lamy syndrome and cleidocranial dysplasia are also present.

Dentigerous cysts mostly involve mandibular third molar teeth, followed by maxillary canine and maxillary third molar teeth. Though DC cases are seen in a wide age range, they are mostly observed during the second or third decades of life, and infrequently, during the first decade of life.^[4] In earlier years, the only type of dentigerous cyst that was well known in literature was

How to cite this article: Khan MK, Jindal MK. Successful Management of Large Dentigerous Cyst with Spontaneous Eruption of Affected Teeth by Minimal Invasive Surgical Approach: A Case Report. J Pediatr Dent 2023;x(x):00-00

OPEN ACCESS This work is licensed under a Creative Commons Attribution-NonCommercial 4.0 International License.



the developmental type. However, during the last few decades, two types of dentigerous cysts have been reported and described on the basis of their origins, i.e., developmental type and inflammatory type.[5] These cysts are usually clinically asymptomatic, but they may become painful on secondary infection. Therefore they are identified occasionally, and they are generally identified on routine radiographic examinations.

If a dentigerous cyst is left untreated, it may cause complications, such as pathologic bone fracture, impaction of the permanent tooth, bone deformation, ameloblastoma, and development of squamous cell carcinoma or mucoepidermoid carcinoma.[1,6]

So far, in the existing literature, there is a scarcity of case reports in which a spontaneous eruption of three displaced permanent teeth was managed by the decompression surgical technique has been reported. [1] This article presents the case report of a successful conservative and minimal invasive surgical management of a large inflammatory dentigerous cyst that was associated with a grossly carious primary molar, and that involved three unerupted developing permanent teeth of mandible in a 12 years old, male pediatric patient. The six months long follow-up depicting the favorable healing of the cystic lesion along with the resolution of the facial asymmetry, and the spontaneous eruption of all the involved permanent teeth has been described in this case report.

The manuscript of this case report has been written as per the CARE case reporting guidelines.

Case Report

The case of a 12 years old, male patient whose chief complaint was a hard swelling, that has been going on through the past year on the right side of his face, has been reported to the outpatient department of pediatric dentistry. Patient's parents revealed that the painless hard swelling has been gradually increasing in size for the last year. His medical history and drug history were non-significant. No apparent history was found regarding any kind of past illnesses, hospitalization or trauma to the jaw region. Past dental history revealed the irregular oral hygiene practices of the patient. Patient's family and psychosocial history were not relevant.

On general examination, it was found that the patient was apparently healthy. On extra-oral examination, a non-tender firm swelling with buccal bulge over the right body of the mandible was found (Fig. 1a, b). The

facial asymmetry which was caused due to the buccal bulge of the swelling on the right side of the face was noted (Fig. 1a, b). There were no signs of inflammation. Regional lymph nodes were not palpable. There were no sensory or motor deficits in the facial region. On intra-oral examination, a non-tender hard swelling of approximately 2.5x2.0 cm dimensions that was obliterating the buccal vestibule with the expansion of buccal cortical plate in relation to the teeth regions, 83, 84, 85 and 46, of the right body of mandible region was found (Fig. 1c, d). The lingual cortical plate was intact. The typical "egg-shell cracking" was felt by palpating the teeth regions, 83 and 84. Overlying oral mucosa of the swelling was apparently normal (Fig. 1c, d). Grossly carious tooth, 84, and carious tooth, 74, were observed (Fig. 1d). Poor oral hygiene status, high plaque and calculus score, and abundant stains were observed in the patient.

A thorough radiographic examination was carried out. Orthopantomography (OPG) revealed that the well-defined unilocular radiolucency with sclerotic-border was extending antero-posteriorly from the tooth region, 42, to the tooth region, 46, and supero-inferiorly from roots of the involved teeth to lower border of right body of mandible (Fig. 2a). The radiolucency was involving the crowns of unerupted and developing permanent teeth: 44 (Nolla's stage 6), 45 (Nolla's stage 7) and 43 (Nolla's stage 7). Grossly carious tooth, 84, with resorbed roots was noted (Fig. 2a). A mixed-dentition stage was present. A more detailed and accurate location and extensions of the cystic lesion were revealed in the axial, sagittal, coronal and 3D sections of contrast enhanced computed tomography scan (CECT) (Fig. 2b, c).

Differential diagnosis included dentigerous cyst, radicular cyst, unicystic ameloblastoma, keratogenic odontogenic tumor (KOT) and ameloblastic fibroma.

Based on the case history, a detailed clinical and radiographic examination of the patient was carried out, and the provisional diagnosis of the inflammatory type dentigerous cyst was determined.

Fluid was aspirated from the dome-shaped swelling, and then, it was sent for aspiration cytology, as well as for microbiological examination. Aspirated fluid was apparently a brownish-red colored, thick fluid. Aspirate smear showed neutrophil cells (PMNL), lymphocytes, macrophage and degenerate cells. Culture report of aspirated fluid confirmed the negative microbial growth. All the routine blood examination tests were advised and found within normal limits.

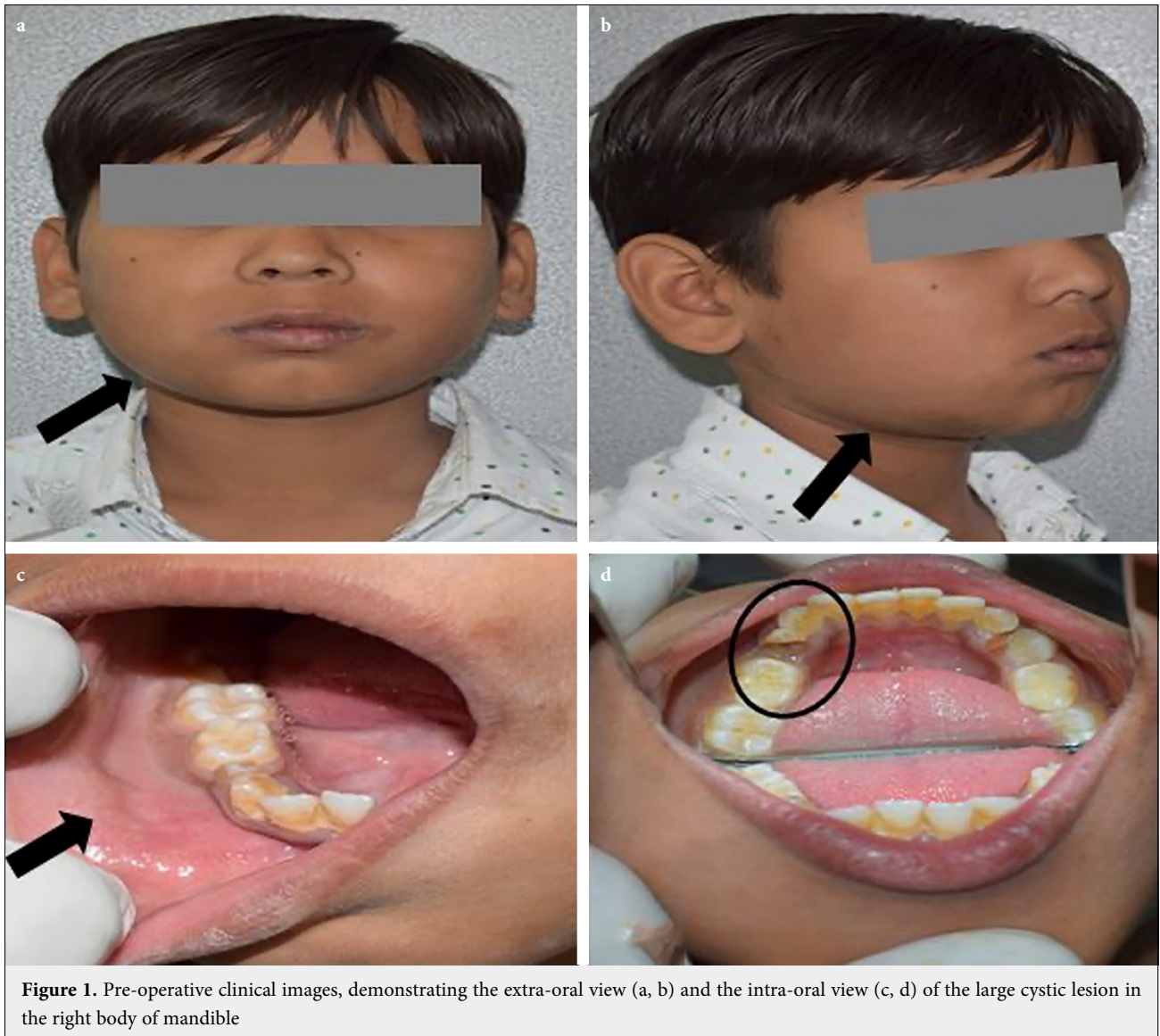

Figure 1. Pre-operative clinical images, demonstrating the extra-oral view (a, b) and the intra-oral view (c, d) of the large cystic lesion in the right body of mandible

Considering the fact that the patient was at his growing period, the size and extension of the lesion, and the dentition status, marsupialization was decided as the treatment plan. Patient's parents were informed about the diagnosis, prognosis, and treatment modalities for the lesion and they were given the necessary explanations regarding these issues. The importance of the long-term follow-up clinical evaluation and home care of the marsupialized cystic cavity was told to the patient's parents. A written informed consent was obtained from the parents before the surgical procedure.

Pre-anesthetic evaluation of the patient was done by the anesthesiology department. Surgical procedure was carried out under general anesthesia. Marsupialization and evacuation of the cystic content of the lesion were done by creating a surgical window through extraction of the involved deciduous teeth, 83, 84 and 85 (Fig. 3a). Cystic

content was surgically removed without extracting the unerupted developing teeth (43, 44 and 45) (Fig. 3b). Cystic lumen was irrigated with copious irrigation with normal saline and betadine solution, followed by the dressing of iodoform-glycerin gauze being placed into the cystic cavity (Fig. 3c, d). Patient was prescribed antibiotics and NSAIDs for five days. A surgical specimen of cyst-lining was sent for histopathological examination. Patient and his parents were sent home after being given all the necessary post-operative instructions. Patient was recalled after 24 hours and was found normal and asymptomatic in the post-operative clinical evaluation (Fig. 4a, b). Patient was advised to maintain oral hygiene. After every interval of two days, the patient was recalled to the clinic for changing the dressing. Later, the patient and parents were advised to irrigate the treated cystic-cavity at home, with betadine-

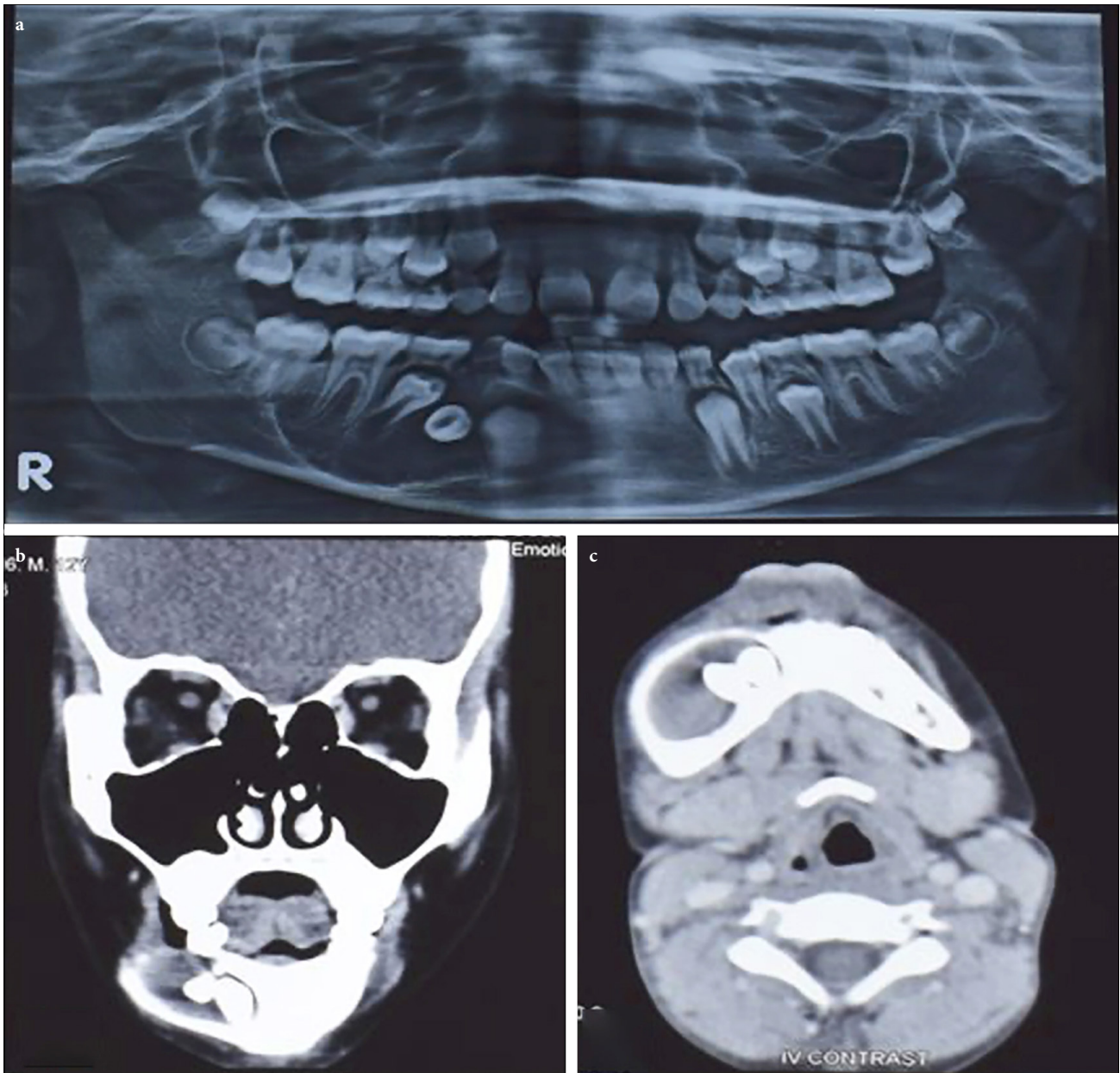


Figure 2. Pre-operative radiographic images showing the characteristic features of the large dentigerous cyst in right body of mandible: OPG radiograph (a), contrast-enhanced CT-scan radiograph (b, c)

OPG: Orthopantomography, CT: Computed tomography

normal saline solution twice a day. The report of histopathological examination confirmed the definitive diagnosis of dentigerous cyst.

During the follow-up visits, after one month (Fig. 5a, b), three months (Fig. 6a, b) and six months (Fig. 7a, b), patient showed favorable healing outcomes with progressive reduction of the radiolucency and with spontaneous eruption of the unerupted developing teeth, 43, 44 and 45. Furthermore, facial asymmetry was also resolved in the follow-up visits (Figs. 6, 7). The orth-

odontic intervention has been advised to the patient for the complete alignment and detailing of the erupted tooth, 44, into the dental arch.

Discussion

Earlier, dentigerous cysts of developmental origin were mostly known in impacted mature permanent teeth, predominantly mandibular third molar, in young adults.[7,8] Later, many authors reported that inflammatory type of dentigerous cysts also exists. Such den-

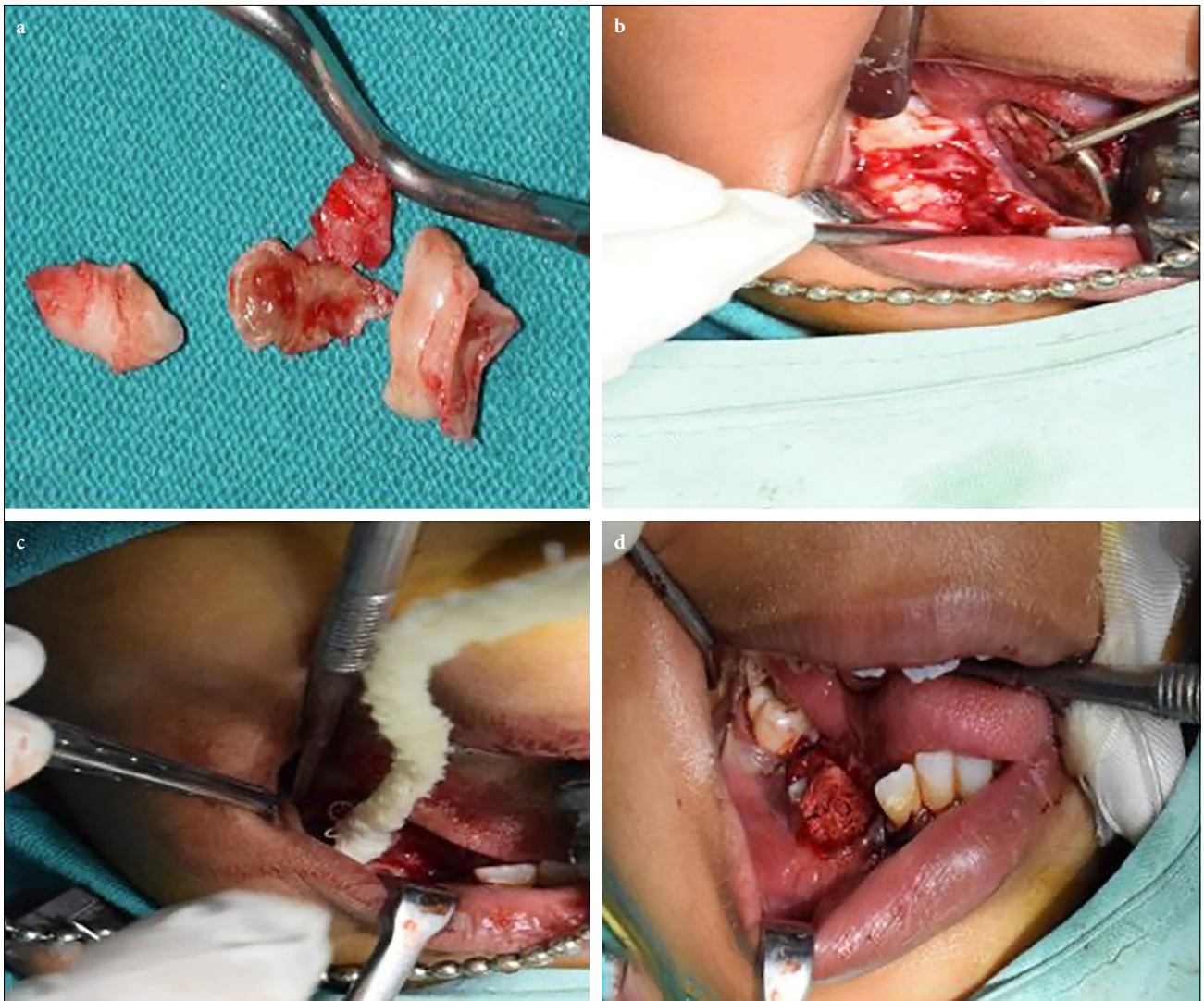


Figure 3. Intra-operative photographs, showing the marsupialization procedure with extraction of carious deciduous teeth

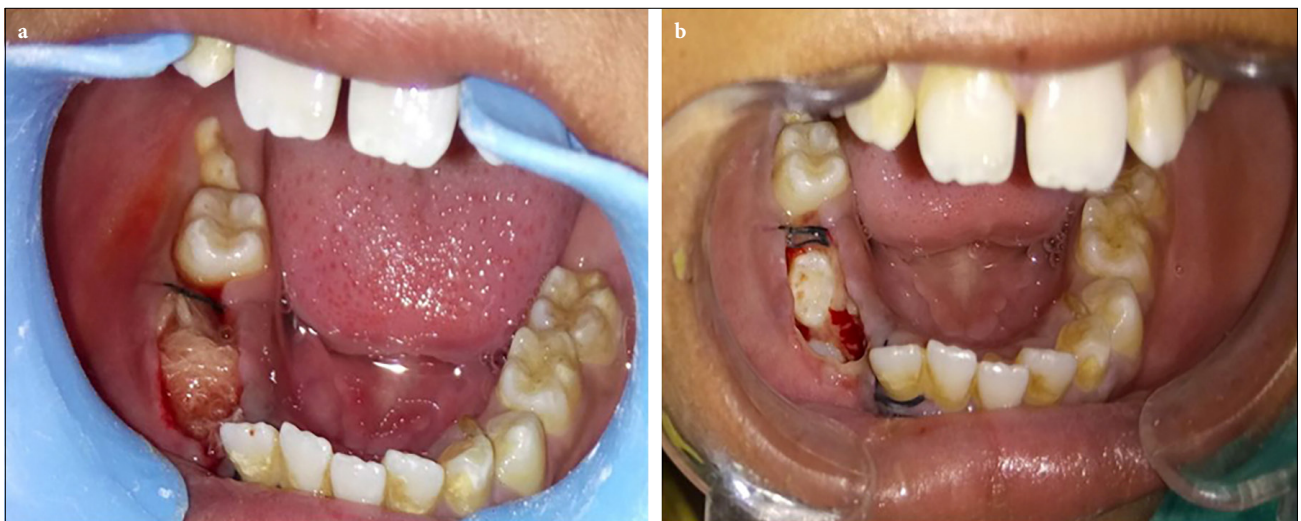


Figure 4. Post-operative images on the third day after the marsupialization procedure, showing that the healing process is normal thanks to the dressing of iodoform with glycerin into the marsupialized cavity (a), and that the unerupted tooth, 45, is visible inside the marsupialized cavity (b)

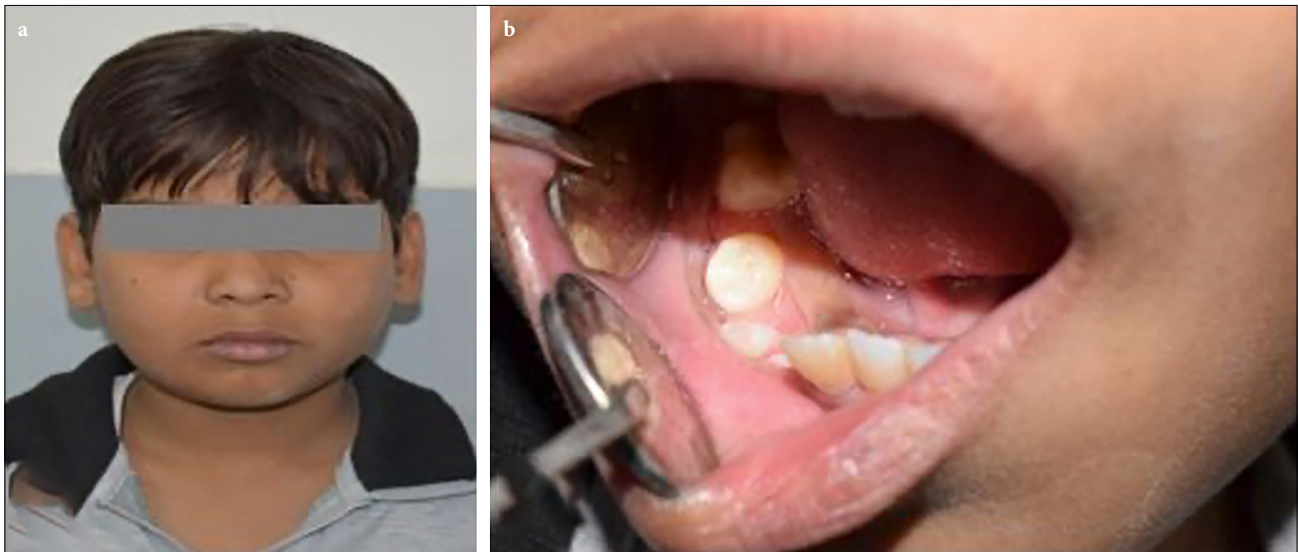

Figure 5. Follow-up images after one month, showing the good healing outcomes.

tigerous cysts of inflammatory origin are associated with the non-vital deciduous teeth, and they enclose the immature developing permanent teeth within the jaw in the patients' first or early second decades of life.[8]

Inflammation, which either comes from a non-vital primary tooth or from any other source, involving the tooth follicle of underlying successor tooth (mostly premolars) is believed to be the origin of dentigerous cysts of inflammatory type in children.[5,8]

Although dentigerous cysts are usually asymptomatic, if not timely addressed, they may cause serious complications, such as pathologic bone fracture, malignancy transformation, and facial deformity. Preservation of developing permanent teeth and inferior alveolar nerve in children by conservative surgical approach is of paramount importance. Furthermore, higher healing potential, bone regeneration potential, and also the higher eruption capacity of immature roots of the unerupted teeth make the marsupialization a successful and effective procedure for the affected children.

Establishing a differential diagnosis in such cystic lesions is crucial for making the definitive diagnosis with the help of a detailed case history, clinical and radiographic examination findings. In the current case, aspiration cytology, and microbial culture were also considered to be among the possible diagnoses to investigate in order to make a correct diagnosis. Histopathologic examination report of surgical specimen confirmed dentigerous cyst.

In the current case, there was a large dentigerous cyst that was associated with the root of a grossly carious

tooth, 84, that involved three unerupted immature permanent teeth, 43, 44 and 45, and that was extending up to inferior border of right mandible along with expansion of buccal cortical plate.

In this case, marsupialization was adopted for treating the larger DC. Firstly, extraction of the carious deciduous teeth was done, creating a window into the cystic cavity through the extracted socket. Then, cystic content was evacuated, and the marsupialized cystic cavity was left open for decompression and shrinkage through the healing process. The surgical treatment results were found very satisfactory in terms of faster healing, bone formation in the cystic-cavity, resolution of facial asymmetry and spontaneous eruption of all three involved displaced teeth. Patient and his parents were very happy and satisfied with the treatment outcomes during the follow-up visits. Similar to the present case, a few other case reports have reported the marsupialization (decompression) approach for inflammatory dentigerous cysts in pediatric patients.[1,4]

As described in literature, the marsupialized cavity is kept open post-operatively by means of iodoform gauze pack, tubes for decompression, retainers stents and stents fixed by mini-screws.[9] Ghandour et al[10] also reported that they used the iodoform gauze for keeping marsupialized cavity open. It also helps in preventing the occurrence of infection in the treated cavity.[11,12]

Complete enucleation (Partsch-II Technique) is a conventional surgical method for the developmental dentigerous cysts which are associated with impacted permanent teeth in adult patients. In this particular proce-

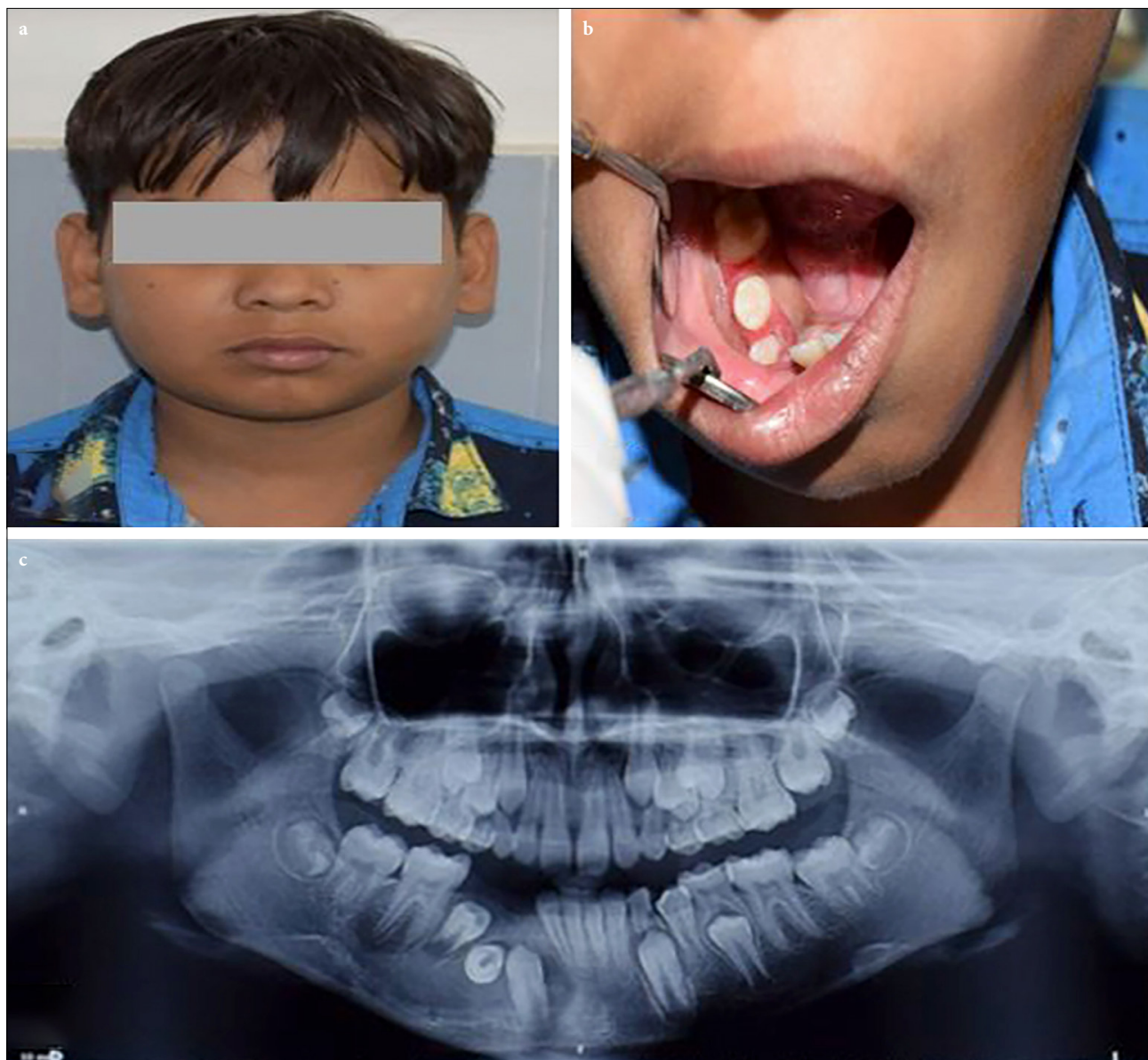

Figure 6. Follow-up photographs and radiographic images after three months of optimum healing process with the start of spontaneous eruption of the affected permanent teeth, 44 and 45, into the oral cavity (a-c)

ture, surgical removal of the associated impacted tooth, along with the complete enucleation of the cystic lesion, is done.[7,8] However, such an aggressive surgical approach is not advisable for the inflammatory dentigerous cysts in children with mixed dentition stage.[7,8] In literature, the possible complications of enucleation procedure have been reported such as the risk of damaging the important anatomical structures (inferior alveolar nerve and associated vasculature and maxillary sinus, and also an increased risk of fracture of the facial bones, mostly mandible, in larger cysts).[7]

The inflammatory dentigerous cysts in pediatric patients are treated by a conservative and a lesser inva-

sive surgical approach known as the marsupialization procedure. It is also known as Decompression or Partsch-I technique. This approach is advised in order to save the associated permanent tooth from being lost. [7,8] Other advantages of employing this approach are as follows: A shorter duration of surgery, a less traumatic surgery for the child patients (lesser invasive in nature), an approach that helps in maintaining the pulp vitality of the adjacent teeth and in preservation of the adjacent important anatomical structures.[7]

Marsupialization, or decompression surgical modality, requires patient's cooperation and compliance for the regular dressing change of the marsupialized cavity, for

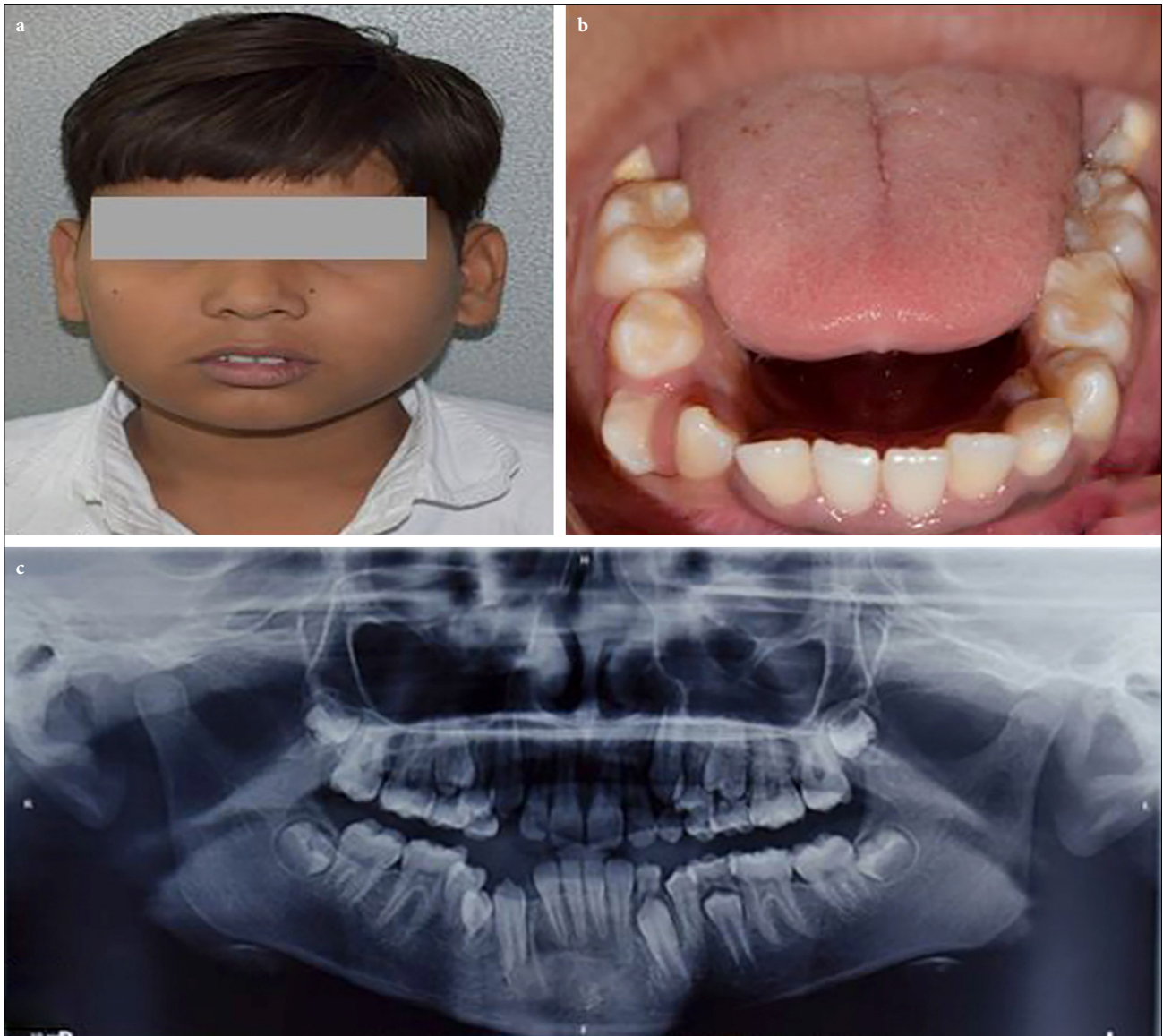

Figure 7. Follow-up images after six months, showing the complete resolution of swelling on right mandible (a), spontaneous eruption of the impacted teeth, 43, 44 and 45, into the oral cavity (b), and OPG radiograph revealing the optimum bony healing of cystic cavity (c)

OPG: Orthopantomography

keeping his/her oral hygiene, for the maintenance, and for the long-term follow-up evaluation till the eruption of the involved permanent teeth and the resolution of the lesion is complete.

In their study, Hyomoto et al[13] evaluated several factors for spontaneous eruption of the impacted tooth in a dentigerous cyst, such as depth of the impacted tooth, angle between the impacted tooth and adjacent teeth, root maturity of the unerupted tooth, the cyst size, and also the eruption space in the dental arch. They concluded that the younger the patient, the greater is the possibility of a spontaneous eruption of an unerupted tooth. 4.4 mm depth of the impacted

tooth, $20.4^{\circ} \pm 21.8^{\circ}$ tooth angulation, and half root undeveloped impacted tooth were reported as favorable factors for spontaneous eruption of the impacted teeth. In 72.4% of the cases, the spontaneous eruption of unerupted premolars after marsupialization was reported.[10,13] In the present case report, all three involved permanent teeth (43, 44 and 45) erupted spontaneously into oral cavity in six months without any orthodontic intervention. All the involved and adjacent teeth showed positive responses on pulp sensitivity tests after the treatment. But, for precise alignment and detailing of the erupted teeth, orthodontic treatment has been advised.

Conclusion

This case report showed that marsupialization procedure is a minimally invasive, effective and successful surgical treatment modality for treating the large dentigerous cyst that is associated with grossly carious deciduous tooth, and that involved multiple unerupted immature permanent teeth of mandible in a growing patient with mixed dentition.

Financial Disclosure: Nil.

Conflict of Interest: None declared.

References

1. Kirtaniya BC, Sachdev V, Singla A, Sharma AK. Marsupialization: a conservative approach for treating dentigerous cyst in children in the mixed dentition. *J Indian Soc Pedod Prev Dent* 2010;28:203–8.
2. Deepa KK, Jannu A, Kulambi M, Shalini HS. A case of dentigerous cyst in a pediatric patient- with an insight into differential diagnostic entities. *Advances in Oral Maxillofac Surg* 2021;3:100130.
3. Ikeshima A, Tamura Y. Differential diagnosis between dentigerous cyst and benign tumor with an embedded tooth. *J Oral Sci* 2002;44:13–7.
4. Bhardwaj B, Sharma S, Chitlangia P, Agarwal P, Bhamboo A, Rastogi K. Mandibular dentigerous cyst in a 10-year-old child. *Int J Clin Pediatr Dent* 2016;9:281–4.
5. Benn A, Altini M. Dentigerous cysts of inflammatory origin. A clinicopathologic study. *Oral Surg Oral Med Oral Pathol Oral Radiol Endod* 1996;81:203–9.
6. Hegde RJ, Khare SS, Devrukhkar VN. Dentigerous cyst in a young child: clinical insight and a case report. *J Indian Soc Pedod Prev Dent* 2013;31:209–11.
7. Joshi M, Samuel S, Abraham A, Deepak DM. Management of dentigerous cysts - a review. *J Evolution Med Dent Sci* 2021;10:1948–53.
8. Al Tuwirqi A, Khzam N. What do we know about dentigerous cysts in children: A review of literature. *J Res Med Dent Sci* 2017;5:67–79.
9. Ertas U, Yavuz MS. Interesting eruption of 4 teeth associated with a large dentigerous cyst in mandible by only marsupialization. *J Oral Maxillofac Surg* 2003;61:728–30.
10. Ghandour L, Bahmad HF, Bou-Assi S. Conservative treatment of dentigerous cyst by marsupialization in a young female patient: A case report and review of the literature. *Case Rep Dent* 2018;2018:7621363.
11. Marwah N, Bishen KA, Prabha V, Goenka P. A conservative approach in the management of inflammatory dentigerous cyst in transitional dentition: a case report. *J Mass Dent Soc* 2012;61:18–21
12. Chouchene F, Ameer WB, Hamdi H, Bouenba M, Masmoudi F, Baaziz A, et al. Conservative approach of a dentigerous cyst. *Case Rep Dent* 2021;2021:5514923.
13. Hyomoto M, Kawakami M, Inoue M, Kirita T. Clinical conditions for eruption of maxillary canines and mandibular premolars associated with dentigerous cysts. *Am J Orthod Dentofacial Orthop* 2003;124:515–20.